

Original Article

Low kilovoltage peak (kVp) with an adaptive statistical iterative reconstruction algorithm in computed tomography urography: evaluation of image quality and radiation dose

Zhiguo Zhou¹, Haixi Chen¹, Wei Wei³, Shanghui Zhou⁴, Jingbo Xu¹, Xifu Wang¹, Qingguo Wang¹, Guixiang Zhang¹, Zhuoli Zhang², Linfeng Zheng^{1,2}

¹Department of Radiology, Shanghai General Hospital, Shanghai Jiao Tong University, Shanghai 200080, China;

²Department of Radiology, Feinberg School of Medicine, Northwestern University, Chicago, IL 60611, USA;

³Department of Surgery, Xiangya Hospital, Central South University, Changsha 410008, China;

⁴Department of Oral and Maxillofacial-Head and Neck Oncology, Shanghai Ninth People's Hospital, Shanghai Jiao Tong University School of Medicine, Shanghai, China

Received February 14, 2016; Accepted June 2, 2016; Epub September 15, 2016; Published September 30, 2016

Abstract: Purpose: The purpose of this study was to evaluate the image quality and radiation dose in computed tomography urography (CTU) images acquired with a low kilovoltage peak (kVp) in combination with an adaptive statistical iterative reconstruction (ASiR) algorithm. Methods: A total of 45 subjects (18 women, 27 men) who underwent CTU with kV assist software for automatic selection of the optimal kVp were included and divided into two groups (A and B) based on the kVp and image reconstruction algorithm: group A consisted of patients who underwent CTU with a 80 or 100 kVp and whose images were reconstructed with the 50% ASiR algorithm (n=32); group B consisted of patients who underwent CTU with a 120 kVp and whose images were reconstructed with the filtered back projection (FBP) algorithm (n=13). The images were separately reconstructed with volume rendering (VR) and maximum intensity projection (MIP). Finally, the image quality was evaluated using an image score, CT attenuation, image noise, the contrast-to-noise ratio (CNR) of the renal pelvis-to-abdominal visceral fat and the signal-to-noise ratio (SNR) of the renal pelvis. The radiation dose was assessed using volume CT dose index (CTDIvol), dose-length product (DLP) and effective dose (ED). Results: For groups A and B, the subjective image scores for the VR reconstruction images were 3.9±0.4 and 3.8±0.4, respectively, while those for the MIP reconstruction images were 3.8±0.4 and 3.6±0.6, respectively. No significant difference was found (p>0.05) between the two groups' image scores for either the VR or MIP reconstruction images. Additionally, the inter-reviewer image scores did not significantly differ (p>0.05). The mean attenuation of the bilateral renal pelvis in group A was significantly higher than that in group B (271.4±57.6 vs. 221.8±35.3 HU, p<0.05), whereas the image noise in group A was significantly lower than that in group B (7.9±2.1 vs. 10.5±2.3 HU, p<0.05). The CNR and SNR in group A were both significantly higher than those in group B (53.61±24.74 vs. 32.30±6.52 for CNR; 38.13±19.86 vs. 21.76±4.85 for SNR; all p<0.05). The CTDIvol, DLP and ED in group A were significantly lower than those in group B (9.26±2.77 vs. 16.19±5.60 mGy for CTDIvol; 368.86±119.38 vs. 674.38±239.37 mGy×cm⁻¹ for DLP; 5.53±1.79 vs. 10.12±3.59 mSv for ED; all p<0.05). Conclusions: The low kVp CTU images with 50% ASiR reconstruction exhibit sufficient image quality and facilitate up to a 44% radiation dose reduction.

Keywords: Computed tomography urography, low kilovoltage peak, adaptive statistical iterative reconstruction (ASiR) algorithm

Introduction

Uroradiology plays an important role in diagnosing several urinary tract disorders, evaluating the anatomy and physiology of the urinary system, and improving outcomes for patients

with urinary tract diseases [1-4]. Traditionally, intravenous urography (IVU), also known as intravenous pyelogram (IVP) or excretory urography (EXU), is commonly performed to investigate the presence of urinary tract stones, hydronephrosis, trauma or tumours due to its

rapid overview of the entire urinary system, its high sensitivity to calcification and obstructions, its ability to facilitate the assessment of both morphology and function and its low cost. However, its disadvantages, which include a requirement of prior bowel preparation, discomfort resulting from compression of the abdomen, an inability to detect small lesions due to its relatively low density resolution, sub-optimal evaluation of the renal parenchyma and the overlapping of anatomical structures or artefacts, have limited its broad application [2, 4]. As a result, in recent decades, computed tomography urography (CTU) has increasingly become an alternative to IVU because of its higher spatial and density resolution, greater sensitivity for detecting urinary system disorders and better visualization of the renal parenchyma [1, 5]. Studies have shown that CTU can be used to identify and evaluate urinary tract trauma and infection, urinary tract abnormalities, upper and lower tract neoplasms and calculi, among others [1, 5-7]. However, there is growing concern about the high radiation dose of CTU and consequences related to radiation exposure [3, 5, 7-9].

To reduce the radiation dose, one of the commonly used strategies is lowering the tube voltage [10, 11]. As a conventional and standard reconstruction algorithm, the filtered back projection (FBP) algorithm has been widely used in CT clinical practice for a number of decades. However, this algorithm is unable to produce high-quality images when high radiation doses are reduced [10-12]. Recently, a series of new reconstruction algorithms, including hybrid iterative reconstruction techniques (IRTs) and model-based iterative reconstruction (MBIR), have been developed to allow lower radiation doses while maintaining the image quality [8, 12-14]. The adaptive statistical iterative reconstruction (ASiR) algorithm is a partially iterative technique that reduces the quantum noise associated with standard convolution FBP reconstruction algorithms, which may result in a reduction in radiation dose and an improvement in image quality compared to the FBP algorithm [11, 14]. Therefore, the purpose of this study was to evaluate the image quality and radiation dose in CTU images acquired with a low kilovoltage peak (kVp) using kV assist software in combination with the ASiR algorithm.

Materials and methods

Ethics

The institutional review board (Shanghai General Hospital Institutional Review Board) approved this retrospective study, and informed consent was waived for all subjects. The patient records were not anonymized or de-identified prior to analysis.

Subject population

Subjects who underwent CTU with kV assist software for automatically selecting the optimal kVp between January 2014 and April 2014 were included in this study. Patients were excluded if they exhibited renal insufficiency, upper urinary tract disorders, or urinary tract obstructions or deformities. Patients in whom the CTU examination failed were also excluded from the study.

CT scanning protocol

All subjects underwent CTU with the same preparation and same protocol on a multi-detector CT scanner (Discovery CT 750 HD, GE Healthcare, Waukesha, MI, USA). All subjects were orally administered approximately 1000 ml of drinking water, and they avoided urinating for 0.5 hr prior to the CT examination. Before a scout scan was performed, the scanner kV assist was turned on, and the kV assist software allowed the optimal kVp to be automatically selected according to the scout image. First, all subjects underwent a pre-contrast phase scan that covered the upper pole of the kidney to the perineal area, with the patient in a supine position. Next, a double-phase (nephrographic and excretory phase) CTU scan was applied with the subjects in a prone position. After the patients were intravenously administered iopamidol (370 mg/ml, Shanghai Bracco Sine Pharmaceutical Corp. Ltd., China) at a dose of 1 ml/kg and a flow rate of 3 ml/s with an automatic power injector (Ulrich medical, Ulm, Germany) followed by 20 ml of 0.9% normal saline flush at the same flow rate, the nephrographic phase scan was started with an 80-second delay. The scan parameters were as follows: interval: 5.0 mm; helical thickness: 5.0 mm; pitch: 0.984; speed: 39.37 mm/rot; and rotation time: 0.7 s. Then, 20 mg of furosemide (Shanghai Harvest Pharmaceutical Co., Ltd.,

Image evaluation of low kVp CTU

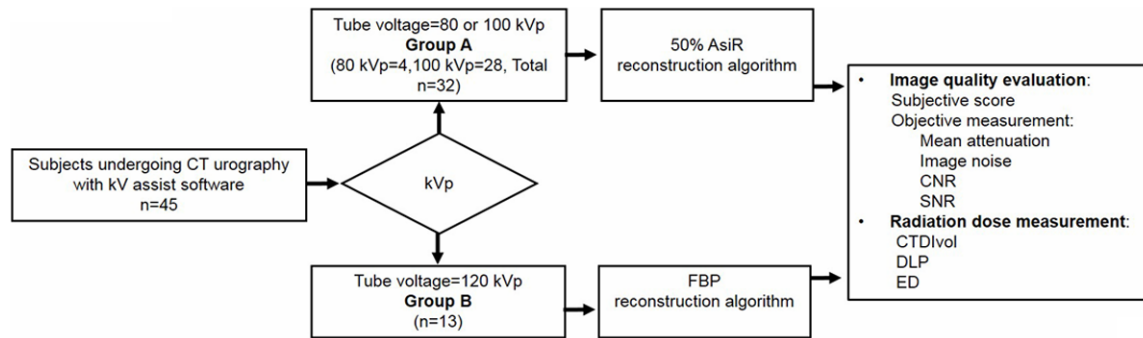


Figure 1. Flow chart illustrating the study design. CT: Computed tomography; kVp: Kilovoltage peak; CTDIvol: Volume CT dose index; CNR: Contrast-to-noise ratio; SNR: Signal-to-noise ratio; DLP: Dose-length product; ED: Effective dose.

China) was intravenously injected and was allowed to pass for 5-10 minutes. Next, an excretory phase scan of the abdomen and the pelvis was conducted using the same parameters employed in the nephrographic phase.

Post-processing and image reconstruction

The patient images acquired with 80 or 100 kVp were reconstructed with the 50% ASiR algorithm (ASiR, GE Healthcare, Milwaukee, WI; Group A, n=32). The patient images acquired with 120 kVp were reconstructed using the standard FBP algorithm (Group B, n=13) (Figure 1). Then, the images from both groups were uploaded to a commercially available workstation (AdvantageWorkstation 4.4; GE Healthcare, Milwaukee, WI), and volume rendering (VR) and maximum intensity projection (MIP) reconstructions were completed. Finally, the reformatted images were uploaded to an image archiving and communication system for image analysis.

Image analysis

Subjective image quality evaluation: The subjective image quality evaluation was based on a four-score scale [5, 15-17]. Both VR and MIP images from groups A and B were reviewed and independently scored by two radiologists (Z.Z. and G.Z., with nine and 20 years of experience in image post-processing, respectively) who were blinded to the group information. The score scale was as follows: 4 (excellent), 3 (good), 2 (fair), and 1 (poor).

Objective image quality measurements: Objective image quality measurements were performed by one radiologist (Z.Z., with nine years of experience in image post-processing). In

axial excretory phase images from both group A and B subjects, a 4-mm² field of interest (FOV) was drawn and placed in the same position of the renal pelvis and abdominal visceral fat. The CT values of the renal pelvis and abdominal visceral fat were measured. For each patient, the region of interest (ROI) of the renal pelvis or abdominal visceral fat in three continuous images was measured. The ROI was held constant for all of the measurements in these three images using the copy-and-paste function at the workstation. The mean CT value of the renal pelvis was defined as the CT image attenuation (CT_{RP}), and the standard deviation (SD) of the CT values in the abdominal visceral fat was defined as the image noise (N_{Fat}) [12, 18]. The signal-to-noise ratio (SNR) in the renal pelvis and the contrast-to-noise ratio (CNR) for the renal pelvis and the abdominal visceral fat were calculated using the following formulas: $SNR = CT_{RP} / N_{Fat}$ and $CNR = (CT_{RP} - CT_{Fat}) / N_{Fat}$, where CT_{Fat} is the CT value for the abdominal visceral fat [12, 18].

Radiation dose measurements: The radiation dose measurements were assessed based on the volume CT dose index (CTDIvol), the dose-length product and the effective dose (ED). The CTDIvol values were automatically calculated by the CT scanner. The DLP was obtained using the following equation: $DLP = CTDIvol \times \text{total scan length}$. The ED was estimated and calculated using the following formula: $ED = DLP \times \text{a conversion coefficient for the abdomen and pelvis}$ ($k = 0.015 \text{ mSv} \times \text{mGy}^{-1} \times \text{cm}^{-1}$) [5, 19].

Statistical analysis

A kappa (k) statistic was applied to assess the inter-radiologist agreement on the subjective

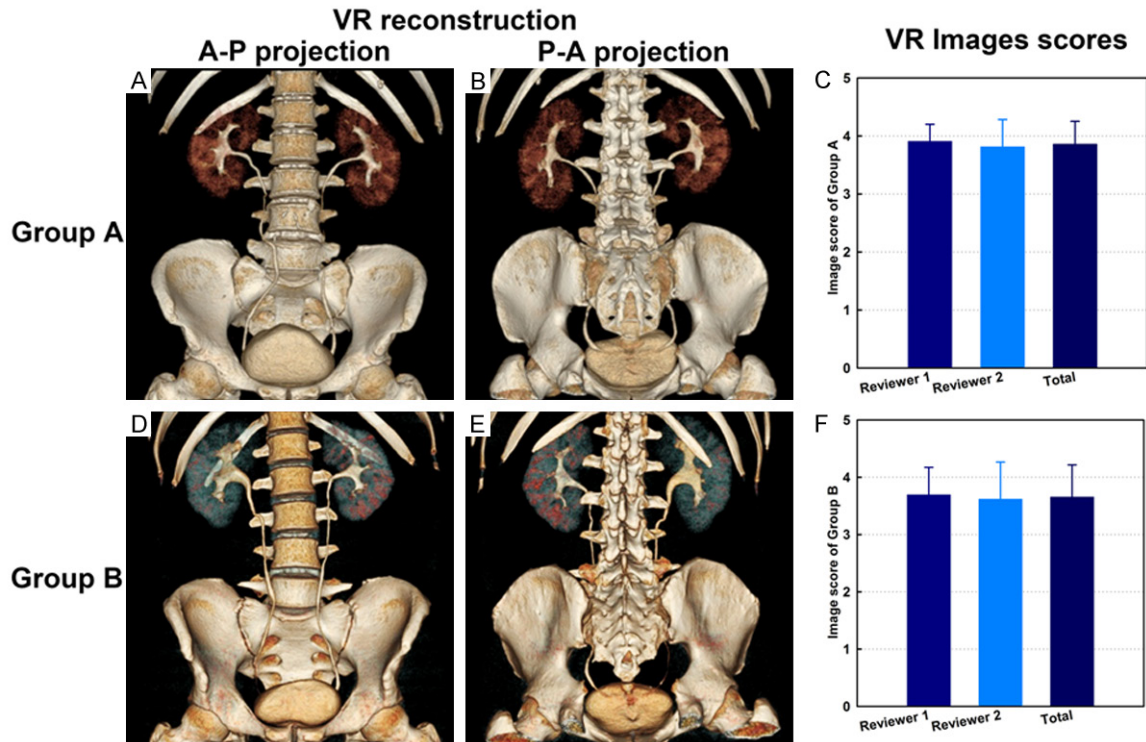


Figure 2. Representative volume rendering (VR) reconstruction images from group A and group B. (A, B) are anterior-posterior A-P and posterior-anterior P-A projection images, respectively, of a subject from group A. (D, E) are A-P and P-A projection images, respectively, of a subject from group B. (C, F) show the subjective image quality scores for groups A and B, respectively.

image quality score; a k coefficient of 0.61–0.80 was considered to indicate substantial inter-observer agreement [20]. Mann-Whitney U tests were used to compare the image scores between groups A and B. The image attenuation, noise, CNR, SNR and radiation dose parameters were analysed using an independent samples Student's t test. Two-sided p -values of less than 0.05 were considered significant. All statistical analyses were performed with IBM SPSS Statistics for Windows Version 22.0 (IBM Corp. Released 2013, Armonk, NY).

Results

General information

A total of 45 consecutive subjects (18 women, 27 men), aged 27 years to 82 years (median age: 60.0 ± 1.3 years [standard deviation]), were included in this study. In total, 32 cases were included in group A, and 13 cases were included in group B. Of the cases in group A, four cases were imaged at 80 kVp, and 28 cases were imaged at 100 kVp (Figure 1).

Subjective image score results

Representative CT VR and MIP reconstruction images from groups A and B are shown in Figures 2 and 3. For groups A and B, the subjective image scores for the VR reconstruction images were 3.9 ± 0.4 and 3.8 ± 0.4 , respectively, (Figure 2C and 2F), whereas those for the MIP images were 3.8 ± 0.4 and 3.6 ± 0.6 , respectively (Figure 3D and 3H). No significant differences were found ($p > 0.05$) between the image scores for groups A and B for either the VR or MIP reconstruction images. Furthermore, the inter-reviewer image scores did not significantly differ ($p > 0.05$).

Objective image quality measurement results

Representative axial excretory phase CTU images illustrating the position of the ROI for the renal pelvis and abdominal visceral fat are shown in Figure 4A. The mean attenuation of the bilateral renal pelvis in group A was significantly higher than that for group B (271.4 ± 57.6 vs. 221.8 ± 35.3 HU, $p < 0.05$; Figure 4B), where-

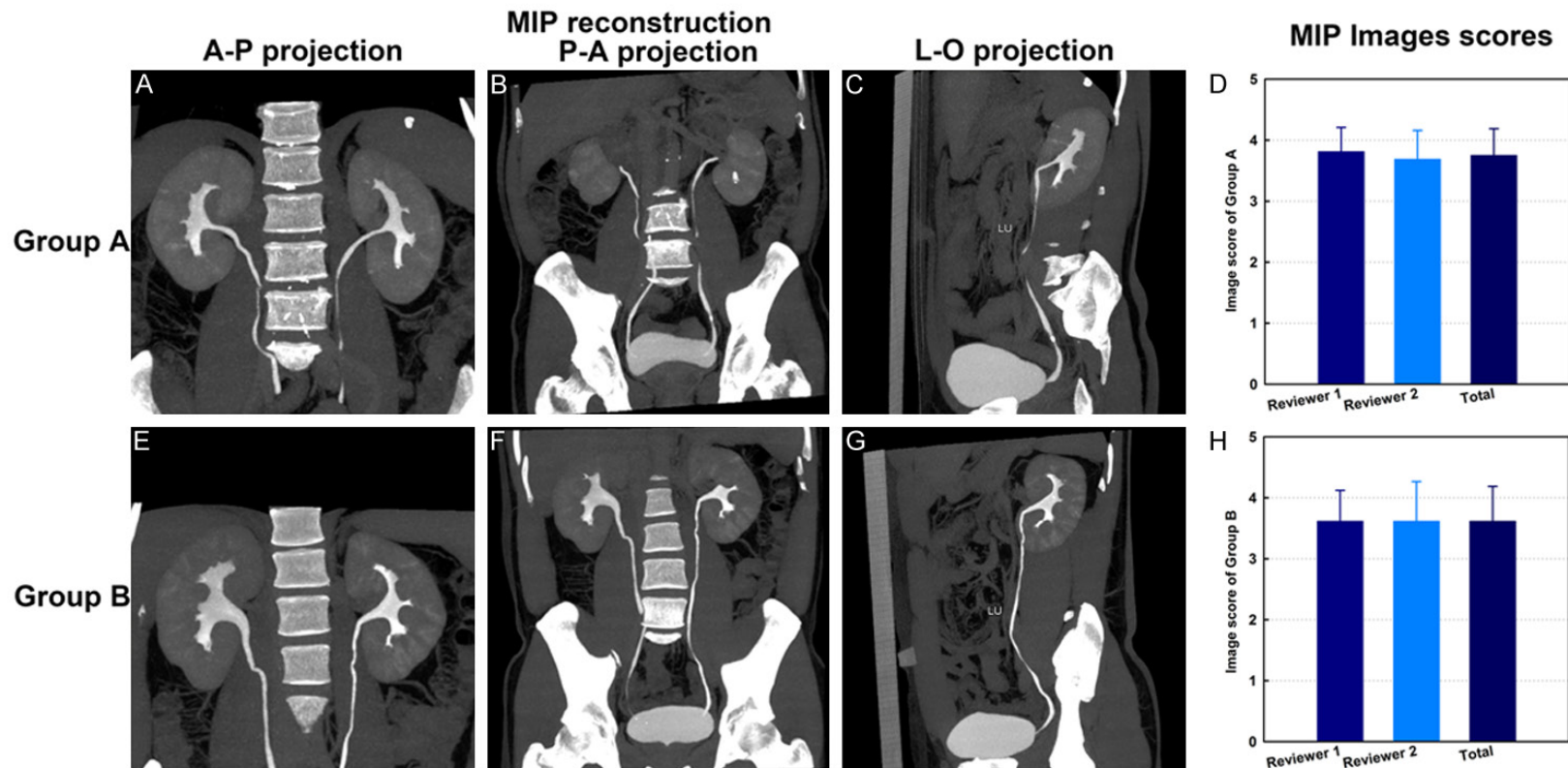


Figure 3. Representative maximum intensity projection (MIP) reconstruction images from groups A and B. (A-C) are anterior-posterior A-P, posterior-anterior P-A, and left-oblique projection images, respectively, of a subject from group A. (E-G) are A-P, P-A and L-O projection images, respectively, of a subject from group B. (D, H) show subjective image quality scores for groups A and B, respectively. The abbreviation LU in (C, G) represents the left ureter.

Image evaluation of low kVp CTU

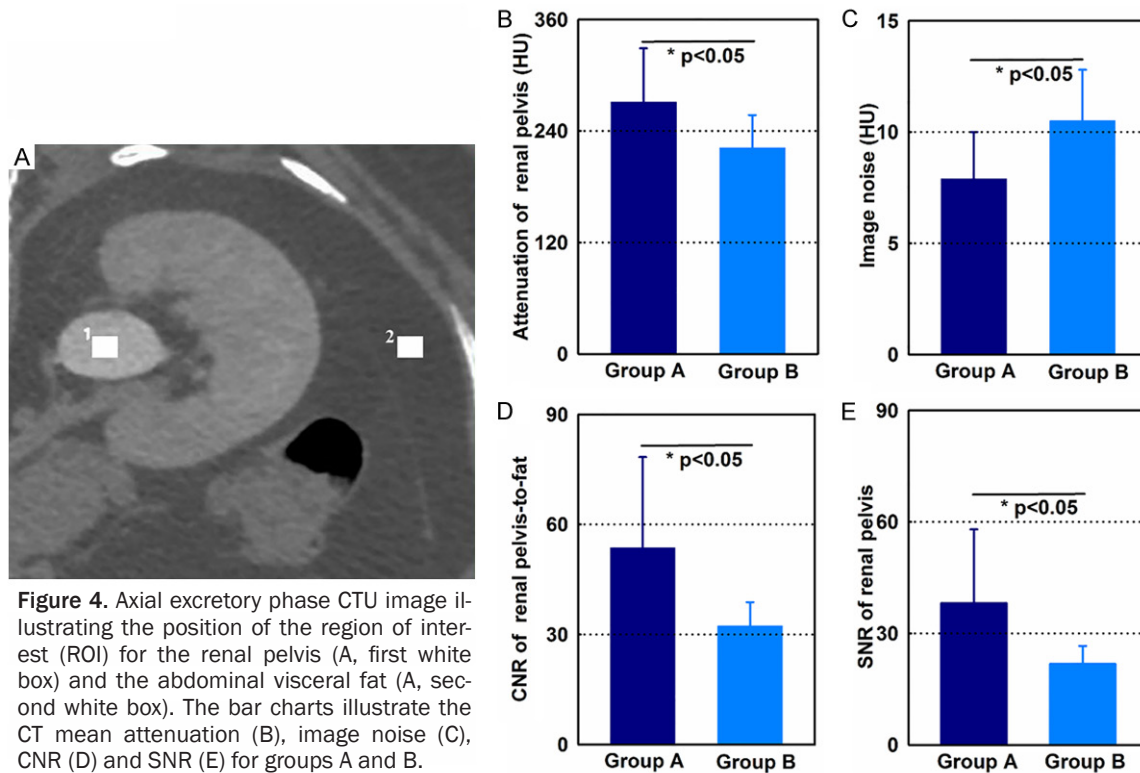


Figure 4. Axial excretory phase CTU image illustrating the position of the region of interest (ROI) for the renal pelvis (A, first white box) and the abdominal visceral fat (A, second white box). The bar charts illustrate the CT mean attenuation (B), image noise (C), CNR (D) and SNR (E) for groups A and B.

as the image noise in group A was significantly lower than that in group B (7.9 ± 2.1 vs. 10.5 ± 2.3 HU, $p < 0.05$; **Figure 4C**). The CNR and SNR in group A were significantly higher than those in group B (53.61 ± 24.74 vs. 32.30 ± 6.52 for CNR; 38.13 ± 19.86 vs. 21.76 ± 4.85 for SNR; all $p < 0.05$; **Figure 4D** and **4E**).

Radiation dose measurement results

The CTDIvol, DLP and ED values for group A were significantly lower than those for group B (9.26 ± 2.77 vs. 16.19 ± 5.60 mGy for CTDIvol; 368.86 ± 119.38 vs. 674.38 ± 239.37 mGy \times cm⁻¹ for DLP; 5.53 ± 1.79 vs. 10.12 ± 3.59 mSv for ED; all $p < 0.05$; **Figure 5**).

Discussion

With the increasing usage of multi-detector CT (MDCT) worldwide, increasing concerns regarding CT radiation doses have been raised by both clinicians and patients. Numerous studies have employed various strategies to minimize the radiation dose while maintaining the image quality in CT examinations [5, 8, 14, 18, 21, 22]. In the present study, we tailored the CTU protocols using 80- or 100-kVp tube voltage

with the 50% ASiR reconstruction algorithm, which maintains image quality while reducing the radiation dose by 44% compared to the use of 120 kVp with the standard FBP reconstruction. Using this protocol, the image ROIs have a higher mean attenuation with reduced image noise. Furthermore, optional SNR and CNR values were achieved, and no loss of subjective image quality was observed in clinical CTU examinations.

In recent decades, CTU has evolved as the first-line urological modality for evaluating abdominal and/or flank pain, haematuria, kidney or bladder stones and tumours of the urinary tract due to its accurate depiction of the kidneys, ureters and urinary bladder [5, 23]. One major challenge related to CTU usage is increased patient radiation exposure when CTU is utilized in clinical practice. A previous study by Nawfel et al [24] demonstrated that standard protocol CTU results in a 1.5-fold higher effective dose compared to conventional urography. With the acceptance of the concept of ALARA (As Low As Reasonably Achievable), several approaches have sought to reduce the radiation dose during CTU scanning by decreasing the tube current [25], reducing the tube

Image evaluation of low kVp CTU

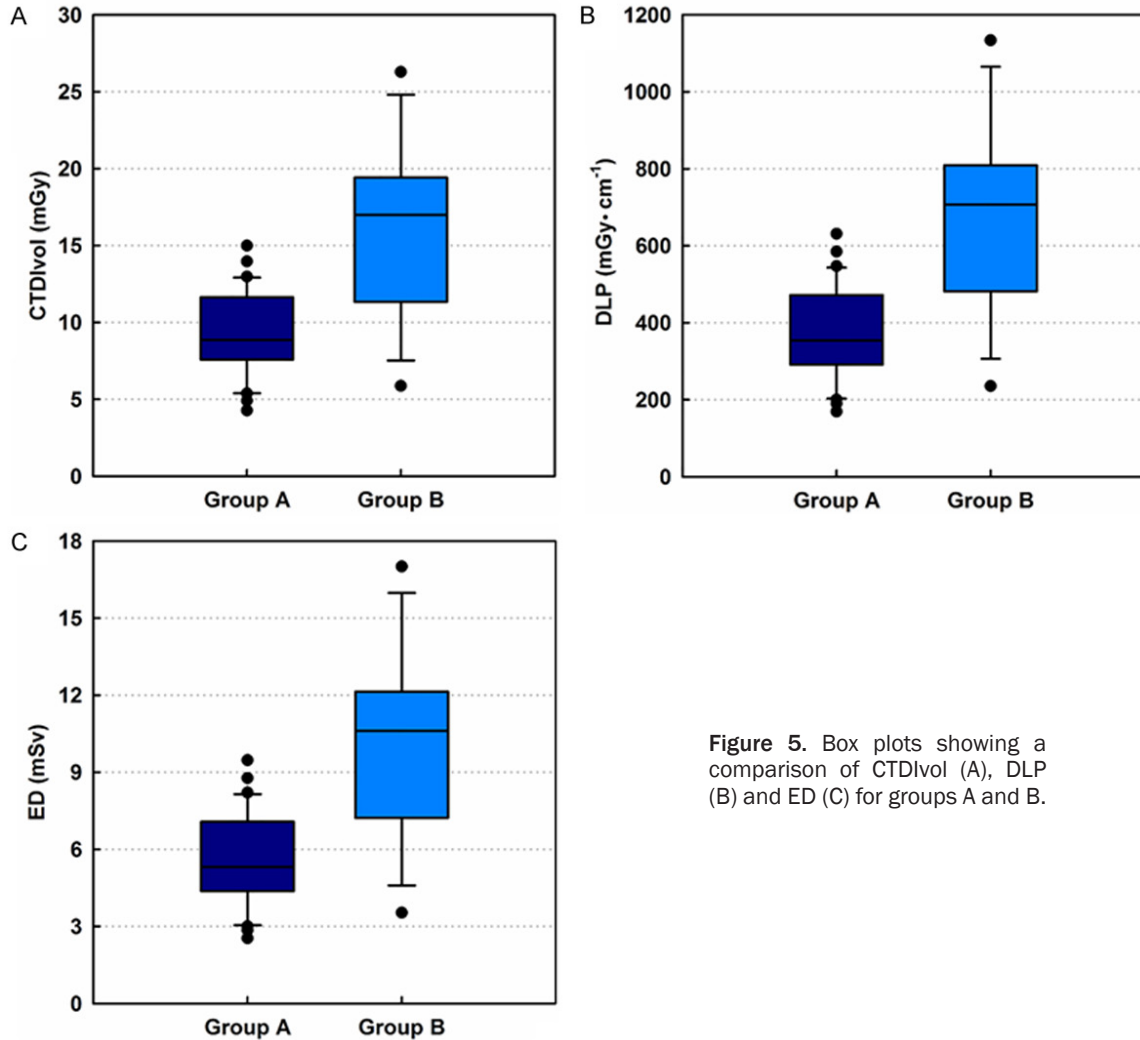


Figure 5. Box plots showing a comparison of CTDIvol (A), DLP (B) and ED (C) for groups A and B.

current-time product [15], lowering the tube voltage [5, 26] or optimizing the CT protocol through changes to the algorithm, software or hardware [7, 23, 27]. Using a multi-detector scanner, both a phantom study by Dr. Coppentrath et al [26] and a clinical study by Dr. Lee et al [5] showed that a low-dose CTU protocol can be implemented using a decreased tube voltage without suffering from a loss of image quality. Therefore, reducing the tube voltage to optimize the CTU protocol is feasible.

ASiR, a partially iterative reconstruction technique, is a newly developed algorithm. Through forward projections and multiple iterative corrections, this algorithm can overcome the drawbacks of limited photon statistics and electronic noise during projection measurements encountered in the conventional FBP technique, resulting in reduced image quantum noise. This

approach can facilitate a lower radiation dose without degrading the spatial or contrast resolution [11-14, 28-30]. In abdominal CT examination, a series of studies has verified that use of the ASiR algorithm reduces the radiation dose by approximately 20-50% while improving the image quality [12, 14, 31]. To date, the feasibility of utilizing the ASiR algorithm for the CTU protocol has not been well validated. To reduce the CTU radiation dose, especially for short stature and small body habitus patients, which are not uncommon in south China and a few Asian countries, we undertook this study to evaluate the application of low kVp with kV assist software in combination with the ASiR algorithm in CTU in comparison to 120 kVp with the traditional FBP algorithm.

In this study, our protocol involved in a selection of ASiR amounts. The ASiR program pro-

vided by the vendors allows users to select ASiR amounts ranging from 10% to 100%. Anecdotal experience with ASiR from several centres has shown that an ASiR>60% produces images with a very artificial and over-smoothed look, which may interfere with the image analysis because most radiologists are accustomed to reading images with some amount of image noise [28, 30, 32]. Therefore, in our pilot study, we selected a value of 50% for the ASiR. Our results showed that the present CTU protocol achieved better image quality with a lower radiation dose.

Several investigators have performed similar studies with ASiR in the urinary tract system. Dr. Kulkarni and coworkers [31] scanned the abdomen and pelvis in 25 patients using the ASiR algorithm and compared their findings to results from 13 patients based on the FBP algorithm. The comparison indicated that the ASiR protocol provides diagnostic-quality images without substantially affecting the diagnostic confidence while allowing for a reduced radiation dose for the evaluation of urinary stone disease. Dr. Bombinski et al [8] recently described CTU examinations performed using ASiR reconstruction techniques in 75 paediatric patients with a range of urinary tract diseases. These authors found that the ASiR algorithm allows for a reduction in the radiation dose in CT examinations and can thus extend the indications for CTU in children. Additionally, in another CTU study, Dr. Juri et al employed adaptive iterative dose reduction (AIDR), a reconstruction technique similar to ASiR provided by Toshiba Medical Systems, to scan 30 patients; their results showed that CTU with AIDR facilitates a 45% reduction in the radiation dose without any loss of image quality in the excretory phase, independent of BMI. Finally, dual-energy CT (DECT) scanners have the potential to allow one CT acquisition during the CTU examination; a few studies and a clinical trial (NCT02283307) using DECT to minimize the CTU dose and to reduce the use of iodinated contrast are on-going [23, 33, 34].

There are several limitations in the present study. First, we did not design a prospective study to test the effect of different kVp values on the same patient using the 50% ASiR reconstruction algorithm or the FBP standard algorithm due to ethical restrictions. However, this disadvantage was partially overcome in our

study because the use of a low kVp (80 or 100 kVp) with the 50% ASiR reconstruction algorithm had no influence on the image quality in either subjective or objective image quality evaluations. Second, this retrospective and single-institute study may have a patient selection bias. When the patients were enrolled in the initial study, we employed an exclusion criterion. Multi-medical centre studies that implement the CTU protocol in all of their patients would strengthen the findings of this study.

In summary, CTU performed using low kVp (80 or 100 kVp) with the 50% ASiR reconstruction algorithm maintains image quality and allows up to a 44% radiation dose reduction compared to the use of 120 kVp with the FBP reconstruction. This approach can be applied to short stature and small body habitus subjects in CTU for clinical practice.

Acknowledgements

The authors would like to thank the technicians at the Department of Radiology, Shanghai General Hospital, Shanghai Jiao Tong University, for CT support. This research was financially supported by the National Natural Science Foundation of China (81271384 and 81371623). Linfeng Zheng is grateful for the State Scholarship Fund from the China Scholarship Council and “The Best Youth Medical Scholars” Award from Shanghai General Hospital, Shanghai Jiao Tong University.

Disclosure of conflict of interest

None.

Address correspondence to: Dr. Linfeng Zheng, Department of Radiology, Shanghai General Hospital, Shanghai Jiao Tong University, 100 Haining Road, Shanghai 200080, China. Tel: +86-21-63240090-4176; Fax: +86-21-63240825; E-mail: zhenglinfeng04@aliyun.com; Zhuoli Zhang, Department of Radiology, Feinberg School of Medicine, Northwestern University, 737 North Michigan Avenue, Suite 1600, Chicago 60611, IL, USA. Tel: +1-312-695-5753; Fax: +1-312-926-5991; E-mail: zhuoli-zhang@northwestern.edu

References

- [1] Morcos SK. Computed tomography urography technique, indications and limitations. *Curr Opin Urol* 2007; 17: 56-64.

Image evaluation of low kVp CTU

- [2] Dyer RB, Chen MY and Zagoria RJ. Intravenous urography: technique and interpretation. *Radiographics* 2001; 21: 799-821; discussion 822-794.
- [3] Van Der Molen AJ, Cowan NC, Mueller-Lisse UG, Nolte-Ernsting CC, Takahashi S and Cohan RH. CT urography: definition, indications and techniques. A guideline for clinical practice. *Eur Radiol* 2008; 18: 4-17.
- [4] Yilmaz S, Sindel T, Arslan G, Ozkaynak C, Karaali K, Kabaalioglu A and Luleci E. Renal colic: comparison of spiral CT, US and IVU in the detection of ureteral calculi. *Eur Radiol* 1998; 8: 212-217.
- [5] Lee S, Jung SE, Rha SE and Byun JY. Reducing radiation in CT urography for hematuria: Effect of using 100 kilovoltage protocol. *Eur J Radiol* 2012; 81: e830-834.
- [6] Sadow CA, Silverman SG, O'Leary MP and Signorovitch JE. Bladder cancer detection with CT urography in an Academic Medical Center. *Radiology* 2008; 249: 195-202.
- [7] Damasio MB, Darge K and Riccabona M. Multidetector CT in the paediatric urinary tract. *Eur J Radiol* 2013; 82: 1118-1125.
- [8] Bombinski P, Warchol S, Brzewski M, Biejat A, Dudek-Warchol T, Krzemien G and Szmigielska A. Lower-dose CT urography (CTU) with iterative reconstruction technique in children-initial experience and examination protocol. *Pol J Radiol* 2014; 79: 137-144.
- [9] Coursey CA and Frush DP. CT and radiation: What radiologists should know. *Appl Radiol* 2008; 37: 22-29.
- [10] Dong F, Davros W, Pozzuto J and Reid J. Optimization of kilovoltage and tube current-exposure time product based on abdominal circumference: an oval phantom study for pediatric abdominal CT. *AJR Am J Roentgenol* 2012; 199: 670-676.
- [11] Patino M, Fuentes JM, Hayano K, Kambadakone AR, Uyeda JW and Sahani DV. A quantitative comparison of noise reduction across five commercial (hybrid and model-based) iterative reconstruction techniques: an anthropomorphic phantom study. *AJR Am J Roentgenol* 2015; 204: W176-183.
- [12] Shuman WP, Chan KT, Busey JM, Mitsumori LM, Choi E, Koprowicz KM and Kanal KM. Standard and reduced radiation dose liver CT images: adaptive statistical iterative reconstruction versus model-based iterative reconstruction-comparison of findings and image quality. *Radiology* 2014; 273: 793-800.
- [13] Singh S, Khawaja RD, Pourjabbar S, Padole A, Lira D and Kalra MK. Iterative image reconstruction and its role in cardiothoracic computed tomography. *J Thorac Imaging* 2013; 28: 355-367.
- [14] Marin D, Nelson RC, Schindera ST, Richard S, Youngblood RS, Yoshizumi TT and Samei E. Low-tube-voltage, high-tube-current multidetector abdominal CT: improved image quality and decreased radiation dose with adaptive statistical iterative reconstruction algorithm-initial clinical experience. *Radiology* 2010; 254: 145-153.
- [15] Kemper J, Regier M, Bansmann PM, Begemann PG, Stork A, Nagel HD, Adam G and Nolte-Ernsting C. Multidetector CT urography: experimental analysis of radiation dose reduction in an animal model. *Eur Radiol* 2007; 17: 2318-2324.
- [16] Roy C, Ohana M, Host P, Alemann G, Labani A, Wattiez A and Lang H. MR urography (MRU) of non-dilated ureter with diuretic administration: Static fluid 2D FSE T2-weighted versus 3D gadolinium T1-weighted GE excretory MR. *Eur J Radiol Open* 2014; 1: 6-13.
- [17] Wang F, Xue H, Yang X, Han W, Qi B, Fan Y, Qian W, Wu Z, Zhang Y and Jin Z. Reduction of metal artifacts from alloy hip prostheses in computer tomography. *J Comput Assist Tomogr* 2014; 38: 828-833.
- [18] Stolzmann P, Leschka S, Scheffel H, Krauss T, Desbiolles L, Plass A, Genoni M, Flohr TG, Wildermuth S, Marincek B and Alkadhi H. Dual-source CT in step-and-shoot mode: noninvasive coronary angiography with low radiation dose. *Radiology* 2008; 249: 71-80.
- [19] Morin RL, Gerber TC and McCollough CH. Radiation dose in computed tomography of the heart. *Circulation* 2003; 107: 917-922.
- [20] Landis JR and Koch GG. The measurement of observer agreement for categorical data. *Biometrics* 1977; 33: 159-174.
- [21] Eller A, May MS, Scharf M, Schmid A, Kuefner M, Uder M and Lell MM. Attenuation-based automatic kilovolt selection in abdominal computed tomography: effects on radiation exposure and image quality. *Invest Radiol* 2012; 47: 559-565.
- [22] Kim MJ, Park CH, Choi SJ, Hwang KH and Kim HS. Multidetector computed tomography chest examinations with low-kilovoltage protocols in adults: effect on image quality and radiation dose. *J Comput Assist Tomogr* 2009; 33: 416-421.
- [23] Silverman SG, Leyendecker Jr and Amis ES Jr. What is the current role of CT urography and MR urography in the evaluation of the urinary tract? *Radiology* 2009; 250: 309-323.
- [24] Nawfel RD, Judy PF, Schleipman AR and Silverman SG. Patient radiation dose at CT urography and conventional urography. *Radiology* 2004; 232: 126-132.
- [25] Mueller-Lisse UL, Copenrath EM, Meindl T, Degenhart C, Scherr MK, Stief CG, Reiser MF

Image evaluation of low kVp CTU

- and Mueller-Lisse UG. Delineation of upper urinary tract segments at MDCT urography in patients with extra-urinary mass lesions: retrospective comparison of standard and low-dose protocols for the excretory phase of imaging. *Eur Radiol* 2011; 21: 378-384.
- [26] Coppenrath E, Meindl T, Herzog P, Khalil R, Mueller-Lisse U, Krenn L, Reiser M and Mueller-Lisse UG. Dose reduction in multidetector CT of the urinary tract. *Studies in a phantom model. Eur Radiol* 2006; 16: 1982-1989.
- [27] Dahlman P, Jangland L, Segelsjo M and Magnusson A. Optimization of computed tomography urography protocol, 1997 to 2008: effects on radiation dose. *Acta Radiol* 2009; 50: 446-454.
- [28] Marin D, Choudhury KR, Gupta RT, Ho LM, Allen BC, Schindera ST, Colsher JG, Samei E and Nelson RC. Clinical impact of an adaptive statistical iterative reconstruction algorithm for detection of hypervascular liver tumours using a low tube voltage, high tube current MDCT technique. *Eur Radiol* 2013; 23: 3325-3335.
- [29] Shuman WP. Adaptive Iterative Reconstruction in CT: What Does It Do? How Can I Use It? Available: <http://www.imagewisely.org/imaging-modalities/computed-tomography/imaging-physicians/articles/adaptive-iterative-reconstruction-in-ct>. Accessed: Apr 26, 2016.
- [30] Flicek KT, Hara AK, Silva AC, Wu Q, Peter MB and Johnson CD. Reducing the radiation dose for CT colonography using adaptive statistical iterative reconstruction: A pilot study. *AJR Am J Roentgenol* 2010; 195: 126-131.
- [31] Kulkarni NM, Uppot RN, Eisner BH and Sahani DV. Radiation dose reduction at multidetector CT with adaptive statistical iterative reconstruction for evaluation of urolithiasis: how low can we go? *Radiology* 2012; 265: 158-166.
- [32] Miller J. Iterative Image Reconstruction Method (ASIR): Lowering CT Radiation Dose and Improving Image Quality. *Radiology Rounds* 2009; 7.
- [33] William S. "Dual Energy CT Urography With Reduced Iodinated Contrast". Available: <https://clinicaltrials.gov/ct2/show/record/NCT02283307>. Accessed: Apr 26, 2016.
- [34] Stolzmann P, Leschka S, Scheffel H, Rentsch K, Baumuller S, Desbiolles L, Schmidt B, Marincek B and Alkadhi H. Characterization of urinary stones with dual-energy CT: improved differentiation using a tin filter. *Invest Radiol* 2010; 45: 1-6.