

Original Article

Morroniside protects against chronic atrophic gastritis in rat via inhibiting inflammation and apoptosis

Ji Zhang¹, Honghua Wang²

¹Department of Traditional Chinese Medicine, ²General Surgery, Xiangshui County People's Hospital, Yancheng 224600, China

Received July 20, 2019; Accepted July 26, 2019; Epub September 15, 2019; Published September 30, 2019

Abstract: The aim of our study was to investigate the therapeutic efficacy of Morroniside (MR) in a chronic atrophic gastritis (CAG) rat model and its underlying mechanisms. Male Wistar rats were employed to induce CAG model. All animals were divided into six groups: control, model (CAG), positive (Vitacoenzyme tablets), MR low, middle and high three doses groups. Histopathology observation of gastric tissues was detected by hematoxylin and eosin (H&E) staining. The levels of gastrointestinal hormones and inflammatory factors in serum were measured by Enzyme-linked immunosorbent assay (ELISA). Apoptosis of gastric mucosa cell was detected using Terminal-deoxynucleotidyl Transferase Mediated Nick End Labeling (TUNEL) assay. Protein expressions were evaluated by Western blotting. Obvious pathological injury and in the CAG model group were observed, which was improved after treatment with MR. The contents of serum gastrin (GAS) was increased whereas motilin (MTL) was decreased in a dose-dependent manner after MR treatment. MR markedly attenuated the levels of tumor necrosis factor- α (TNF- α), interleukin-6 (IL-6) and interleukin-1 beta (IL-1 β). Moreover, MR inhibited apoptosis of gastric mucosal cell as presented by TUNEL, coupled with an upregulation in Bcl-2 expression and a downregulation in Bax, cleaved caspase-3 and cleaved caspase-9 expression. Furthermore, the expression levels of phospho-NF- κ B p65 (p-NF- κ B p65) and p-IKK α / β proteins were reduced accompanied by an increase in I κ B- α expression in the MR-treated groups. The study demonstrated that MR is able to protect against CAG via inhibiting inflammation and apoptosis, which might provide a stronger theoretical basis for the treatment of CAG.

Keywords: Chronic atrophic gastritis, inflammation, apoptosis, Morroniside

Introduction

Chronic atrophic gastritis (CAG) is a kind of the most common digestive diseases worldwide, and it is characterized as a precancerous lesion of intestinal type gastric cancer (GC) with a high prevalence [1, 2]. It has been well documented that the incidence of CAG has been increasing accompanied by a decreasing average age of clinical patients in recent years [3]. CAG has repeated lingering condition, and the risk of cancer enhances when it is related to intestinal metaplasia and dysplasia, which contributed to the predicament of clinical treatment [4]. Therefore, effective treatment of CAG is urgently in order to suppress CAG progression and prevent its early transformation to GC.

With deepening researches, a sustained inflammatory reaction and abnormal apoptosis of ga-

stric mucosa are confirmed as important causes in the pathogenesis of CAG, which have drawn growing attention [5, 6]. Morroniside (MR), a extract from *Cornus officinalis*, possesses the most abundant iridoid glycosides [7]. A recent investigation has shown that MR could attenuate myocardial damage apoptosis through inhibiting inflammation activation [8]. In addition, the previous study demonstrated that MR suppresses H₂O₂-induced apoptosis in PC12 cells [9]. Moreover, MR was thought to also have the ability to decrease the activation of caspase-3 and -9 while upregulate the expression of Bcl-2 [10]. However, studies reporting on the effect of MR on CAG and its mechanism are very limited, which arouses our interests.

In our present study, we investigated the therapeutic efficacy of MR in a rat model and its underlying regulatory mechanisms, which might

provide a stronger theoretical basis for the treatment of CAG.

Material and methods

Experimental animals

All SPF-grad male Wistar rats (8-week-old, 200±20 g) were provided by Shanghai SLAC Laboratory Animal Company Limited (Shanghai, China). All animals were housed in cages in an air-conditioned animal room with 12 h light/dark cycle. They were allowed to acclimate to the environment with free access to normal food and water for one week before the experiment. All procedures and animal care in the present study was carried out adhering to the guidelines for the Care and Use of Laboratory Animals and approved by the Ministry of Science and Technology of China. All of the study protocols were approved by the Ethics Committee on Animal Experiments of Xiangshui County People's Hospital.

Animal treatment

After a habituation for one week, all animals were divided into six groups randomly (n=6) including control group, model (CAG) group, positive group (Vitacoenzyme tablets, 200 mg/kg), Morroniside low (20 mg/kg), middle (40 mg/kg) and high (60 mg/kg) three doses groups. Morroniside (HPLC grade, purity >98%) was obtained from Pureone Biological Technology Co. Ltd. (Shanghai, China). The control group had free access to normal food and water. Consistent with previous studies, animals in other groups were administrated freely with N-methyl-N'-nitro-N-nitrosoguanidine (MN-NG, 200 µg/mL; Tokyo Kabushiki Kaisha, Japan) combined with irregular diet (one day of enough food and one day of fasting, alternating between the two) for 12 weeks [11, 12]. Then, rats in drug-treated groups were intragastrically administrated with drug for eight consecutive weeks. And rats in the control group were given sterile distilled water with the same volume and frequency. After the experiment was finished, all rats were anesthetized. Blood and gastric tissues were harvested for subsequent assays.

Histopathological observation

The gastric tissues from six groups' rats were conventionally fixed in 10% formalin overnight.

After dehydration, these tissues were embedded in paraffin. Strips of tissue were sectioned into 5 µm slices, mounted on slides and stained with hematoxylin and eosin (HE) for conventional morphological evaluation. Then, all the sections were dehydrated with graded ethanol and xylene. The slides (n=8) were examined by an experienced pathologist blind to the treatments, under a light microscope (Olympus Corp., Tokyo, Japan) using 100× magnification (100 fields per section).

Enzyme-linked immunosorbent assay (ELISA)

The concentrations of gastrin (GAS), motilin (MTL), tumor necrosis factor- α (TNF- α), interleukin-6 (IL-6) and interleukin-1 beta (IL-1 β) in serum were measured by ELISA kits in accordance with the manufacturer's instructions for each kit. The ELISA kits of GAS (F1-5482), MTL (F16197), TNF- α (F16961), IL-1 β (F15810) and IL-6 (F15870) were all the products of Shanghai Xitang Biotechnology Co., Ltd. (Shanghai, China).

Terminal-deoxynucleotidyl Transferase Mediated Nick End Labeling (TUNEL) assay

TUNEL staining of gastric mucosa cell was performed using the TUNEL FITC Apoptosis detection kit (Vazyme, Nanjing, China). After fixation, clearing, washing, equalization, labeling, washing, staining, and washing, cell apoptosis was observed by green fluorescence microscopy (400× magnification).

Western blot assay

The total proteins in gastric tissues were extracted using RIPA buffer (Beyotime, Shanghai, China). A BCA Protein Quantitation kit (Beyotime, Shanghai, China) was applied to measure protein concentration according to the manufacturer's instructions. Then, 40 µg/lane protein in each sample was loaded onto the 12% SDS-PAGE, and proteins were transferred to polyvinylidene fluoride (PVDF; Merck Millipore, Billerica, MA) membranes by electrophoresis. Subsequently, 5% non-fat dry milk was employed to soak these membranes. After that, membranes were incubated with the primary antibodies and the reaction was kept overnight at 4°C. Next, all blots were incubated with fluorescent secondary (cat. no. A0208; Beyotime Institute of Biotechnology, Haimen, China) antibody at

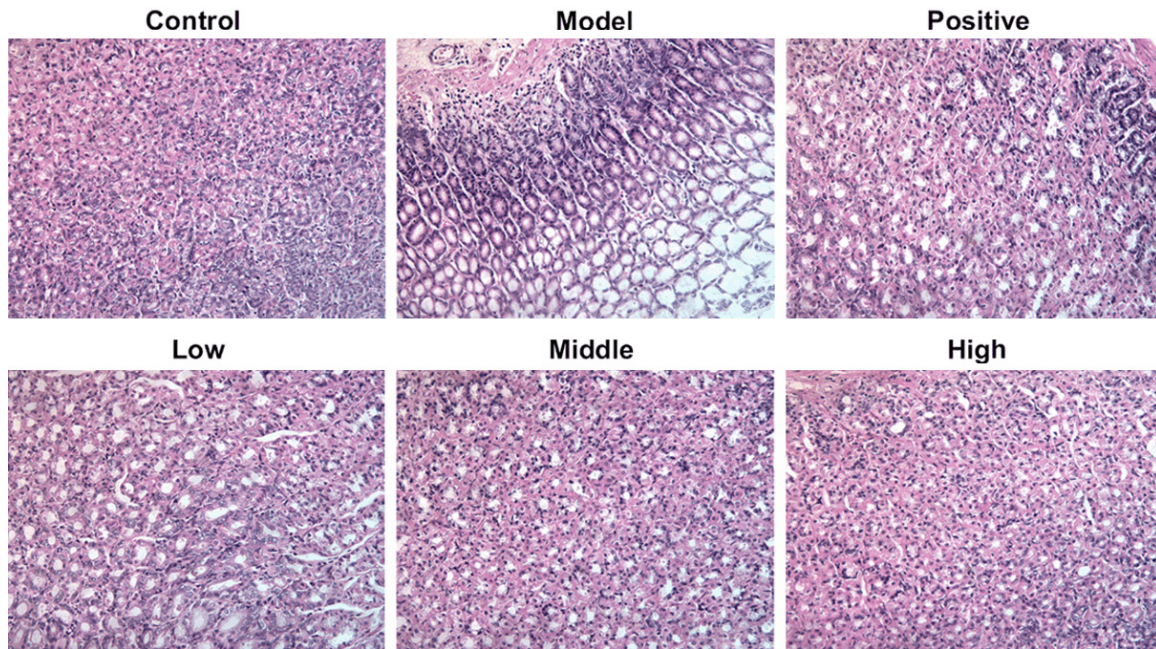


Figure 1. MR relieved histological lesions of gastric tissues in CAG rats induced by MNNG combined with irregular diet. Representative images of H&E staining from each experimental group. (magnification, $\times 100$). MR, Morroniside; CAG, chronic atrophic gastritis; MNNG, N-methyl-N'-nitro-N-nitrosoguanidine; H&E, hematoxylin and eosin.

room temperature for 1 h. An Odyssey infrared imaging system (Lincoln, NE) was applied to visualization and Image J software (1.46r) was used to analyze the results. GAPDH was employed to control for equal loading. Anti-Bcl-2 (cat. no. sc-7382) was the product of Santa Cruz Biotechnology (USA). Anti-Bax (cat. no. 14796S), anti-caspase-3 (cat. no. 14220T), anti-cleaved caspase-3 (cat. no. 9661S), anti-caspase-9 (cat. no. 9508T), anti-cleaved caspase-9 (cat. no. 3195S), anti-NF- κ B p65 (cat. no. 8242S), anti-p-NF- κ B p65 (cat. 3033S), anti-IKK α / β (cat. no. 61294S), anti-p-IKK α / β (cat. no. 2697S), anti-IkB- α (cat. no. 4812S) and anti-GAPDH (cat. no. 5174S) antibodies were obtained from Cell Signaling Technology (Boston, MA, USA).

Statistical analysis

All experimental data were displayed as mean \pm SD. SPSS 14.0 software (Chicago, IL) was applied to statistical analyses. Statistical comparisons were made by two-tailed Student's t test or one way analysis of variance (ANOVA). A value of $P < 0.05$ was thought statistically significant. All experiments were performed with at least three replicates.

Results

MR relieved histological lesions of gastric tissues in CAG rats

In order to investigate the therapeutic efficacy of MR on CAG rats, gastric tissues was obtained and H&E staining was employed to detect the pathological changes. As presented in **Figure 1**, cystic dilation, irregular arrangement and inflammatory cells infiltration were found in gastric tissues of model group rats compared with control group, which demonstrated that CAG rat model was established successfully. Above symptoms were improved in a concentration-dependent manner after treatment with MR as seen by regular arrangement and markedly decrease in inflammatory cells infiltration. These results suggest that MR could relieve histological lesions of gastric tissues in CAG rats.

MR affected the levels of gastrointestinal hormones in serum of CAG rats

We measured the levels of gastrointestinal hormones in serum of CAG rats. We found that the content of GAS in serum of rat was reduced whereas MTL was enhanced after administra-

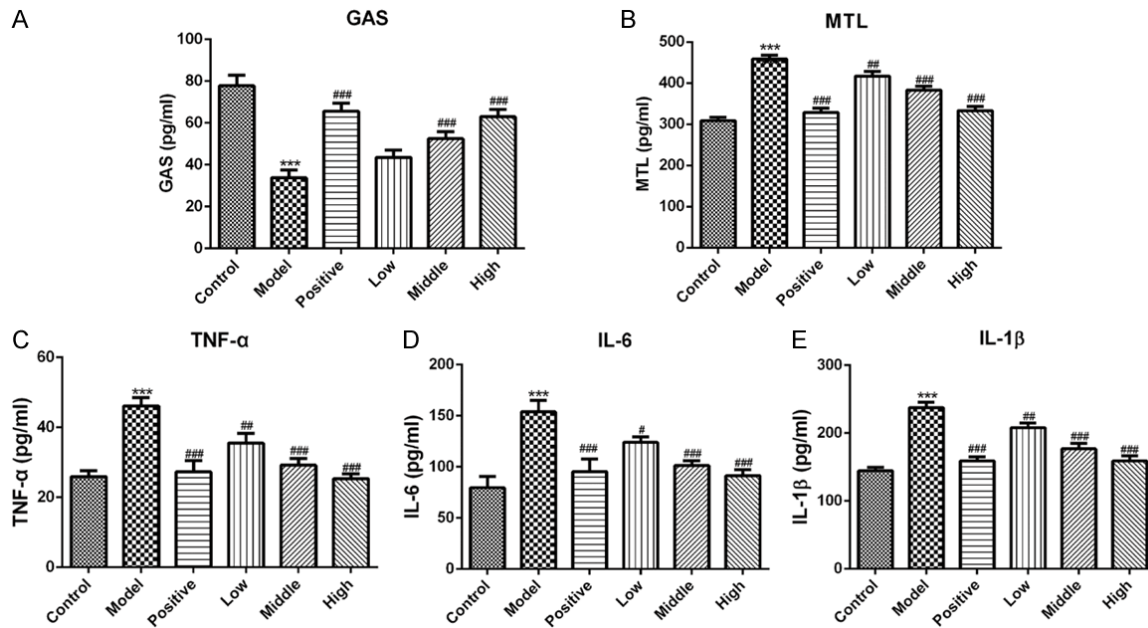


Figure 2. MR regulated the levels of gastrointestinal hormones and inflammatory cytokines in serum of CAG rats induced by MNNG combined with irregular diet. The levels of gastrointestinal hormones including (A) GAS and (B) MTL were measured by the related ELISA kits. The contents of inflammatory cytokines including (C) TNF- α , (D) IL-6 and (E) IL-1 β were detected using ELISA kits. ***P<0.001 vs. control; ##P<0.01, ###P<0.001 vs. model. MR, Morroniside; CAG, chronic atrophic gastritis; GAS, gastrin; MTL, motilin; TNF- α , tumor necrosis factor-alpha; IL-6, interleukin-6; IL-1 β , interleukin-1 beta; ELISA, Enzyme-linked immunosorbent assay; MNNG, N-methyl-N'-nitro-N-nitrosoguanidine.

tion with MNNG combined with irregular diet (**Figure 2A** and **2B**). Speaking of the effect of MR, the level of GAS was obviously increased coupled with a decrease of MTL level in a dose-dependent way. Above data indicate that MR treatment improves the levels of gastrointestinal hormones CAG rats.

MR attenuated the concentration of inflammatory cytokines in serum of CAG rats

Inflammatory cytokines including TNF- α , IL-6 and IL-1 β play important roles in the pathological process of CAG. Therefore, above cytokines were measured using ELISA in our study. As shown in **Figure 2C-E**, the levels of TNF- α , IL-6 and IL-1 β were increasing significantly in model group compared with control group. On the contrary, the levels of these factors were lowered following treatment with MR, which suggested that MR inhibits the generation of inflammatory cytokines in CAG rats.

MR inhibited apoptosis of gastric mucosal cell in CAG rats

To explore the effect of MR on apoptosis of gastric mucosal cell, TUNEL staining was applied to

perform this analysis and the result was presented in **Figure 3**. Gastric mucosal cell of rats in CAG model group exhibited higher level of apoptosis than control group. When it comes with MR treatment group, the apoptosis index of gastric mucosal cell reduced in a dose-independent manner. Additionally, western blotting assay was employed to evaluate the expression of apoptosis associated proteins. We found that the level of anti-apoptosis protein Bcl-2 was decreased coupled with an increase of pro-apoptotic proteins including Bax, cleaved caspase-3 and cleaved caspase-9 following rats being administrated with MNNG combined with irregular diet alone (**Figure 4**). Importantly, MR treatment reversed the reduced Bcl-2 and enhanced Bax, cleaved caspase-3 and cleaved caspase-9. Above results indicate that MR suppresses apoptosis of gastric mucosal cell in CAG rats.

MR suppressed NF- κ B signaling in CAG rats

To further investigate the regulatory mechanisms of MR on CAG, the expression of NF- κ B signaling was detected by western blotting. As presented in **Figure 5**, the expression of p-NF-

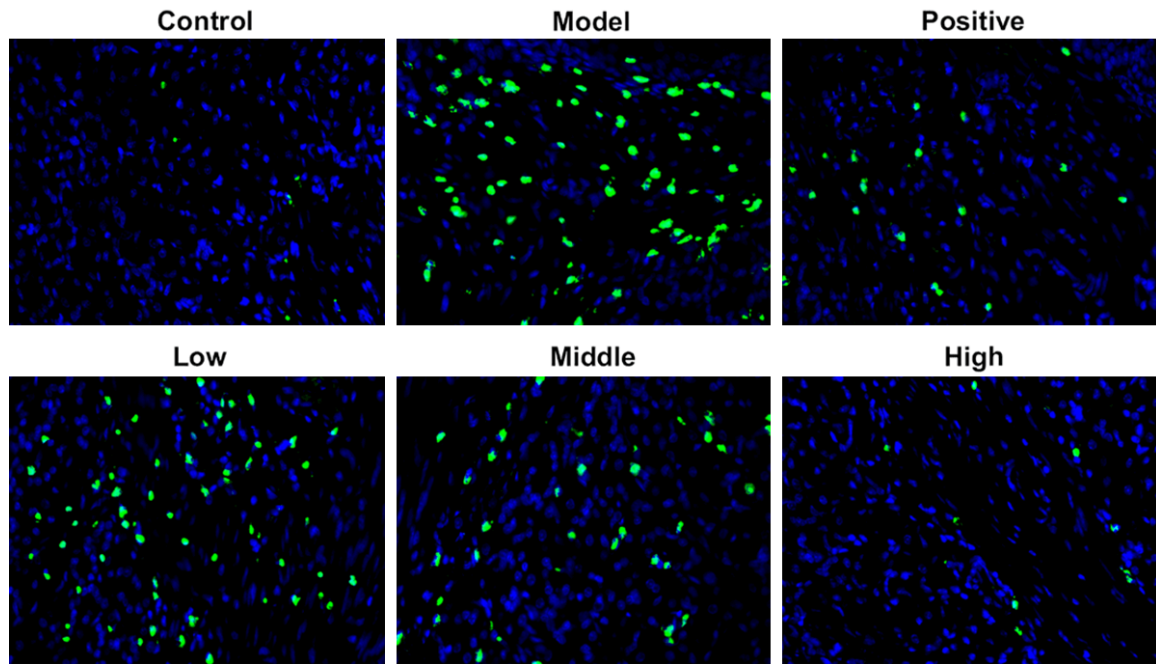


Figure 3. MR inhibited apoptosis of gastric mucosal cells in CAG rats induced by MNNG combined with irregular diet. Representative images of cell apoptosis were evaluated by TUNEL (magnification, $\times 400$). MR, Morroniside; CAG, chronic atrophic gastritis; TUNEL, Terminal-deoxynucleotidyl Transferase Mediated Nick End Labeling.

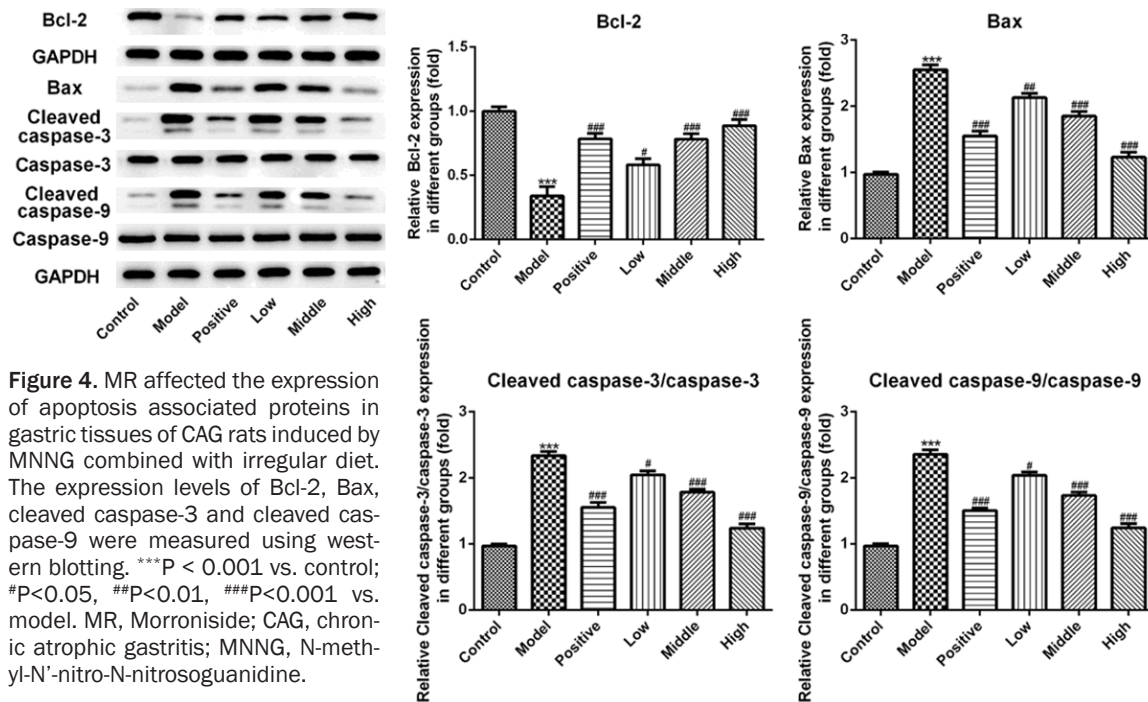


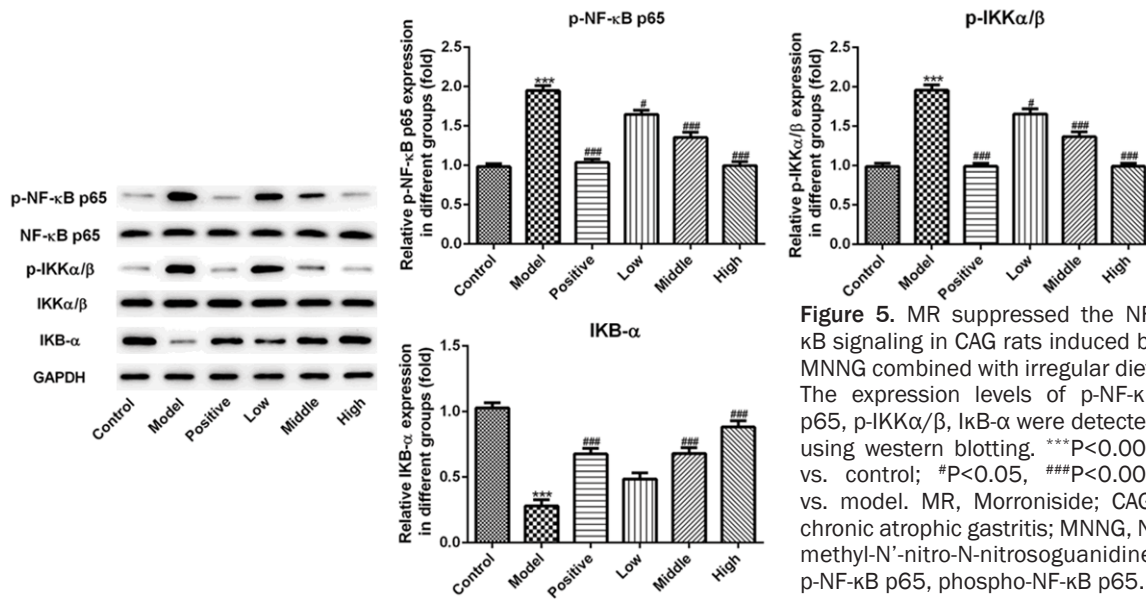
Figure 4. MR affected the expression of apoptosis associated proteins in gastric tissues of CAG rats induced by MNNG combined with irregular diet. The expression levels of Bcl-2, Bax, cleaved caspase-3 and cleaved caspase-9 were measured using western blotting. ^{***} $P < 0.001$ vs. control; [#] $P < 0.05$, ^{##} $P < 0.01$, ^{###} $P < 0.001$ vs. model. MR, Morroniside; CAG, chronic atrophic gastritis; MNNG, N-methyl-N'-nitro-N-nitrosoguanidine.

κ B p65 and p-IKK α / β were upregulated notably whereas I κ B- α was downregulated in model group. Speaking of the effect of MR, MR treatment decreased the levels of p-NF- κ B p65 and p-IKK α / β while increasing the level of I κ B- α in a concentration-dependent manner. The results indicate that MR protects against CAG induced

MNNG combined with irregular diet via suppressing NF- κ B signaling.

Discussion

CAG is a kind of the most common digestive diseases global, which is famous for as a pre-



cancerous lesion of intestinal type gastric cancer (GC) [3]. With the rising incidence and younger age of onset, CAG seriously influence the health and quality of life of more and more patients [13]. The lack of specific therapeutic agents for CAG aroused the research interests of us about finding new and effective drugs. In our study, we found that MR treatment alleviated pathological changes of CAG in rats induced by MNNG combined with irregular diet, and the underlying mechanisms might be related to the inhibition of inflammation and apoptosis of gastric tissues. Taken together, our data suggest that MR is able to a potential therapeutic agent for the clinical treatment of CAG.

MR belongs to an extensive group of iridoid glycosides, which are extracted from *Cornus officinalis*. Accumulating evidence shows that MR possesses a plenty of beneficial pharmacological effects such as neuroprotection, anti-oxidative stress, anti-inflammation and anti-apoptosis activities [14, 15]. However, the effect of MR on CAG remains to be elucidated. In the current study, we found that MR treatment dose-dependently mitigated the histological lesions of gastric tissues in CAG rats. GAS, a major nutrient of gastric mucosa, plays significant roles in nutrition and protective effects on gastric mucosa. Additionally, MTL is an important gastrointestinal hormone related to gastric motility, which can induce strong gastric contraction and promote the secretion of pepsin and food digestion [16]. Clinical studies have found that

MTL levels in serum of patients with GC are significantly higher than normal [17]. Our present study suggested that MR administration enhance the level of GAS and reduced the level of MTL, which was in accordance with the previous study [5]. Above data demonstrate that MR can protect against CAG induced by MNNG combined with irregular diet.

Mounting evidence supported that the secretion of pro-inflammatory cytokines including IL-6, IL-1β and TNF-α exerts crucial effects in the development course of CAG [18, 19]. It has been well reported that MR is able to regulate inflammation of liver in type 2 diabetic db/db mice [20]. MR mitigates myocardial damage apoptosis induce by coxsackievirus B3 through inhibiting NLRP3 inflammasome activation [21]. Importantly, MR could decrease the levels of IL-6, IL-1β and TNF-α in myocardium of acute myocardial infarction rats [8]. MR administration in the present study notably decreased the expression of TNF-α, IL-6 and IL-1β in a dose-independent manner. Based on the above results, we demonstrate that MR relieves gastric mucosa injury of CAG via restraining inflammation.

It has been well reported that MR can suppress neuron apoptosis and abrogate cerebral ischemia/reperfusion injury [22]. In addition, the previous study demonstrated that MR suppresses H₂O₂-induced apoptosis in PC12 cells [9]. MR was thought to also have the ability to

decrease the activation of caspase-3 and -9 while upregulating Bcl-2 expression [10]. A recent research has reported that Notoginsenoside R1 can improve CAG via increasing Bcl-2 expression and decreasing Bax expression in gastric tissue of rats induced by MNNG combined with irregular diet [5]. In our study, MR intervene decreased the degree of gastric mucosal cells apoptosis. At the same time, the expression of anti-apoptosis gene Bcl-2 was upregulated obviously whereas pro-apoptosis genes Bax, cleaved caspase-3 and cleaved caspase-9 were upregulated notably in a dose-independent way following CAG rats being treated with MR. Results of these date were in line with the previous finding [23].

Emerging evidence supports the notion that inhibition of NF- κ B signaling contributes to the treatment of CAG [12, 24]. Study has shown that Qinghuayin, a Chinese formula, protects against CAG through downregulating the expression of NF- κ B signaling [25]. We found that the expression of p-NF- κ B p65 and p-IKK α / β were reduced following treatment with MR in the present study. On the contrary, the level of I κ B- α was increased markedly in a dose-independent manner. The aforementioned results confirmed that MR protects against CAG induced by MNNG combined with irregular diet via suppressing NF- κ B signaling.

Conclusions

In summary, for the first time, MR was applied to explore its therapeutic efficacy on CAG rat induced by MNNG combined with irregular diet. The present study demonstrated that MR is able to treat CAG, which may be attributed to the inhibition of inflammation and apoptosis. Therefore, MR is a promising agent for the treatment of CAG and our findings might provide a stronger theoretical basis for the treatment of CAG.

Acknowledgements

All of the study protocols in the present study were approved by the Ethics Committee on Animal Experiments of Xiangshui County People's Hospital.

Disclosure of conflict of interest

None.

Address correspondence to: Honghua Wang, General Surgery, Xiangshui County People's Hospital, No. 287, Guanhe Road, Xiangshui, Yancheng 22-4600, China. Tel: 0515-86872847; E-mail: wang-honghua1122@163.com

References

- [1] de Vries AC, van Grieken NC, Looman CW, Casparie MK, de Vries E, Meijer GA and Kuipers EJ. Gastric cancer risk in patients with premalignant gastric lesions: a nationwide cohort study in the Netherlands. *Gastroenterology* 2008; 134: 945-952.
- [2] Sugano K. Screening of gastric cancer in Asia. *Best Pract Res Clin Gastroenterol* 2015; 29: 895-905.
- [3] Adamu MA, Weck MN, Rothenbacher D and Brenner H. Incidence and risk factors for the development of chronic atrophic gastritis: five year follow-up of a population-based cohort study. *Int J Cancer* 2011; 128: 1652-1658.
- [4] He TY, Chai JY and Zhao ZT. Sixty-three cases of chronic atrophic gastritis treated by method of turtle-probing needling. *Zhongguo Zhen Jiu* 2011; 31: 91-92.
- [5] Luo C, Sun Z, Li Z, Zheng L and Zhu X. Notoginsenoside R1 (NGR1) attenuates chronic atrophic gastritis in rats. *Med Sci Monit* 2019; 25: 1177-1186.
- [6] Chen P, Cui Y, Fu QY, Lu YY, Fang JY and Chen XY. Positive relationship between p42.3 gene and inflammation in chronic non-atrophic gastritis. *J Dig Dis* 2015; 16: 568-574.
- [7] Liu Z, Zhu Z, Zhang H, Tan G, Chen X and Chai Y. Qualitative and quantitative analysis of Fructus Corni using ultrasound assisted microwave extraction and high performance liquid chromatography coupled with diode array UV detection and time-of-flight mass spectrometry. *J Pharm Biomed Anal* 2011; 55: 557-562.
- [8] Yu B, Zhang G, An Y and Wang W. Morroniside on anti-inflammation activities in rats following acute myocardial infarction. *Korean J Physiol Pharmacol* 2018; 22: 17-21.
- [9] Chen K, Lu Y, Liu C, Zhang L, Fang Z and Yu G. Morroniside prevents H₂O₂ or Abeta1-42-induced apoptosis via attenuating JNK and p38 MAPK phosphorylation. *Eur J Pharmacol* 2018; 834: 295-304.
- [10] Pi WX, Feng XP, Ye LH and Cai BC. Combination of Morroniside and diosgenin prevents high glucose-induced cardiomyocytes apoptosis. *Molecules* 2017; 22.
- [11] Zhu X, Liu S, Zhou J, Wang H, Fu R, Wu X, Wang J and Lu F. Effect of Astragalus polysaccharides on chronic atrophic gastritis induced by N-methyl-N'-nitro-N-nitrosoguanidine in rats. *Drug Res (Stuttg)* 2013; 63: 597-602.

- [12] Zhang J, Huang K, Zhong G, Huang Y, Li S, Qu S and Zhang J. Acupuncture decreases NF-kappaB p65, miR-155, and miR-21 and increases miR-146a expression in chronic atrophic gastritis rats. *Evid Based Complement Alternat Med* 2016; 2016: 9404629.
- [13] Zhang L, Liu Y, You P and Feng G. Occurrence of gastric cancer in patients with atrophic gastritis during long-term follow-up. *Scand J Gastroenterol* 2018; 53: 843-848.
- [14] Wang H, Gao P, Jing L, Qin X and Sun X. The heart-protective mechanism of nitronyl nitroxide radicals on murine viral myocarditis induced by CVB3. *Biochimie* 2012; 94: 1951-1959.
- [15] Wang W, Sun F, An Y, Ai H, Zhang L, Huang W and Li L. Morroniside protects human neuroblastoma SH-SY5Y cells against hydrogen peroxide-induced cytotoxicity. *Eur J Pharmacol* 2009; 613: 19-23.
- [16] Kitazawa T and Kaiya H. Regulation of gastrointestinal motility by motilin and ghrelin in vertebrates. *Front Endocrinol (Lausanne)* 2019; 10: 278.
- [17] Gao L, Zhao Z, Zhang L and Shao G. Effect of early oral feeding on gastrointestinal function recovery in postoperative gastric cancer patients: a prospective study. *J BUON* 2019; 24: 194-200.
- [18] Chen J, Wang W, Zhang T, Ji J, Qian Q, Lu L, Fu H, Jin W and Cui D. Differential expression of phospholipase C epsilon 1 is associated with chronic atrophic gastritis and gastric cancer. *PLoS One* 2012; 7: e47563.
- [19] Jeong M, Park JM, Han YM, Kangwan N, Kwon SO, Kim BN, Kim WH and Hahm KB. Dietary intervention of artemisia and green tea extracts to rejuvenate helicobacter pylori-associated chronic atrophic gastritis and to prevent tumorigenesis. *Helicobacter* 2016; 21: 40-59.
- [20] Park CH, Noh JS, Kim JH, Tanaka T, Zhao Q, Matsumoto K, Shibahara N and Yokozawa T. Evaluation of morroniside, iridoid glycoside from Corni Fructus, on diabetes-induced alterations such as oxidative stress, inflammation, and apoptosis in the liver of type 2 diabetic db/db mice. *Biol Pharm Bull* 2011; 34: 1559-1565.
- [21] Li WD CM, Xu LS, et al. Morroniside alleviates coxsackievirus B3-induced myocardial damage apoptosis via restraining NLRP3 inflammasome activation. *RSC Advances* 2019; 9: 1222-1229.
- [22] Zeng G, Ding W, Li Y, Sun M and Deng L. Morroniside protects against cerebral ischemia/reperfusion injury by inhibiting neuron apoptosis and MMP2/9 expression. *Exp Ther Med* 2018; 16: 2229-2234.
- [23] Yoon JH, Lee YS, Kim O, Ashktorab H, Smoot DT, Nam SW and Park WS. NKX6.3 protects against gastric mucosal atrophy by downregulating beta-amyloid production. *World J Gastroenterol* 2019; 25: 330-345.
- [24] Lin HY, Zhao Y, Yu JN, Jiang WW and Sun XL. Effects of traditional Chinese medicine Wei-Wei-Kang-Granule on the expression of EGFR and NF-KB in chronic atrophic gastritis rats. *Afr J Tradit Complement Altern Med* 2012; 9: 1-7.
- [25] Li S, Huang M, Chen Q, Li S, Wang X, Lin J, Zhong G, Lin P and Asakawa T. Confirming the effects of Qinghuayin against chronic atrophic gastritis and a preliminary observation of the involved inflammatory signaling pathways: an in vivo study. *Evid Based Complement Alternat Med* 2018; 2018: 4905089.