

## Original Article

# Osteotomies combined with soft tissue procedures for symptomatic flexible flatfoot deformity in children

Xiaodong Wen<sup>1</sup>, Guanghua Nie<sup>1</sup>, Cheng Liu<sup>1</sup>, Hongmou Zhao<sup>1</sup>, Jun Lu<sup>1</sup>, Xiaojun Liang<sup>1</sup>, Xinwen Wang<sup>1</sup>, Jingqi Liang<sup>1</sup>, Rui Guo<sup>2</sup>, Yi Li<sup>1</sup>

<sup>1</sup>Department of Foot and Ankle Surgery, Honghui Hospital, Xi'an Jiaotong University, Xi'an 710054, China;

<sup>2</sup>Department of Orthopaedics, Shaanxi University of Chinese Medicine, Xianyang 712046, Shaanxi, China

Received June 4, 2020; Accepted October 8, 2020; Epub October 15, 2020; Published October 30, 2020

**Abstract:** Background: The indications for surgery, timing, and procedure in children with flexible flatfoot deformity remain controversial. This study aims to evaluate the efficacy of osteotomies combined with soft tissue procedures in children with flexible flatfoot aged 9-14 years. Methods: Twenty-eight children (47 feet) with flexible flatfoot who underwent osteotomy combined with soft tissue surgery between July 2014 and October 2017 were included in this study. The main observational indexes included the American Orthopedic Foot and Ankle Society (AOFAS) ankle-hindfoot score, Foot and Ankle Outcome Score (FAOS), talar-navicular coverage angle (TNCA), talar-first metatarsal angle (T1MA) on the foot anteroposterior (AP) view, calcaneal pitch angle and Meary's angle on the foot lateral view, and calcaneus valgus angle (CVA) on the Saltzman view. Intra- and interobserver reliabilities were assessed using intra-class correlation coefficient (ICC). Patient's satisfaction was assessed. Results: All patients were followed up for an average duration of 29.7±8.6 months. The results showed that the mean AOFAS and FAOS had improved significantly from 56.6±8.0 and 47.4±9.5 preoperatively to 88.4±3.9 and 83.2±6.8 at final follow-up (P<0.001), respectively. There were statistically significant differences between preoperative and postoperative scores in all FAOS subscales (P<0.001). Radiographic parameters, such as TNCA (P<0.001) and T1MT (P<0.001) on foot AP views, calcaneal pitch angle (P=0.014) and Meary's angle (P<0.001) on foot lateral views, and CVA (P<0.001) on Saltzman views, had improved significantly. We observed overall substantial to perfect intra- and inter-observer agreements for all radiographic measurements preoperatively and final follow-up. All patients and their parents were satisfied with the functional outcomes. Conclusion: Osteotomies combined with soft tissue procedures is an effective strategy for flexible flatfoot deformity in children, as it results in favorable radiographic and functional outcomes.

**Keywords:** Flexible flatfoot, osteotomy, soft tissue procedure, reconstruction, children

## Introduction

Most children with flexible flatfoot frequently encountered in clinical practice are asymptomatic. Clinicians should alleviate their parents' worry and examine patients every six months. However, severe flexible flatfoot deformities in children cause pain and functional limitations in activities of daily living [1]. Conservative procedures include in foot orthoses, physiotherapy, weight control, and medications for pain relief. Children who are symptomatic but have not responded well to management with conservative methods will require surgical interventions [2, 3]. The aim of the surgery is to alleviate symptoms and prevent permanent deformity. However, the indications for surgery, tim-

ing, and procedure in children with flexible flatfoot deformity remain controversial.

There are various procedures for flexible flatfoot in adolescents and young adults, including arthrodesis, arthroereisis, lateral column calcaneal lengthening (LCL), medial displacement of calcaneal osteotomy (MDCO), medial cuneiform opening wedge (Cotton) osteotomy, and soft tissue procedures [4, 5]. Although arthrodesis can restore the alignment, it usually inhibits foot mobility and increases the risk of developing degenerative arthritis of the adjacent joints. Therefore, arthrodesis should be avoided in children. Arthroereisis is a minimally invasive procedure that temporarily blocks the subtalar joint in the corrected position [6, 7]. The rate of

## Combined procedures for children symptomatic flatfoot

complications, including under-correction, over-correction, implant resorption, inflammatory reactions, and persistent pain, has been as high as 30% [8].

Flexible flatfoot, especially with a marked deformity, including hindfoot and forefoot deformities, requires a meticulous operative plan. For example, the heel is in a far more valgus position, for which subtalar arthroereisis does not provide sufficient correction, and therefore osteotomies and additional soft tissue procedures are required [9]. Failure to correct the associated deformities, such as forefoot abduction and gastrocnemius contracture, increases the risk of recurrence [10].

Osteotomies combined with soft tissue interventions can achieve complete correction, which can avoid deformity progression and consequent premature degenerative changes [11]. Osteotomies combined with soft tissue surgery in children aged 9-14 years have been rarely reported. A few research studies reported the outcomes of this strategy for the management of adolescent and young adult flatfoot, and the average age of studied patients was >14 years [9]. The purpose of this study was to evaluate the outcomes of osteotomies combined with soft tissue procedures in children with flexible flatfoot aged 9-14 years. The hypothesis is that the combined procedure is an effective method for correcting flexible flatfoot in children.

### Materials and methods

#### *Subjects*

This retrospective study was approved by the institutional review board. Informed consent was obtained from all patients. Twenty-eight patients (47 feet) with symptomatic flexible flatfoot deformities underwent reconstructive surgery between July 2014 and October 2017. Patients with symptomatic flexible idiopathic flatfoot were included in this retrospective study.

#### *Inclusion and exclusion criteria*

Inclusion criteria: (1) patients who were diagnosed with symptomatic flexible flatfoot deformities; (2) patients who had signed informed consent forms. Exclusion criteria: (1) patients

with neuromuscular disease, tarsal coalition, traumatic flatfoot, congenital vertical talus, and over-correction of cavus foot; (2) patients who underwent conservative methods involving the use of orthotics and ankle brace as well as physical therapy a minimum of 12 months before operation; (3) patients whose data were incomplete.

#### *Preoperative management*

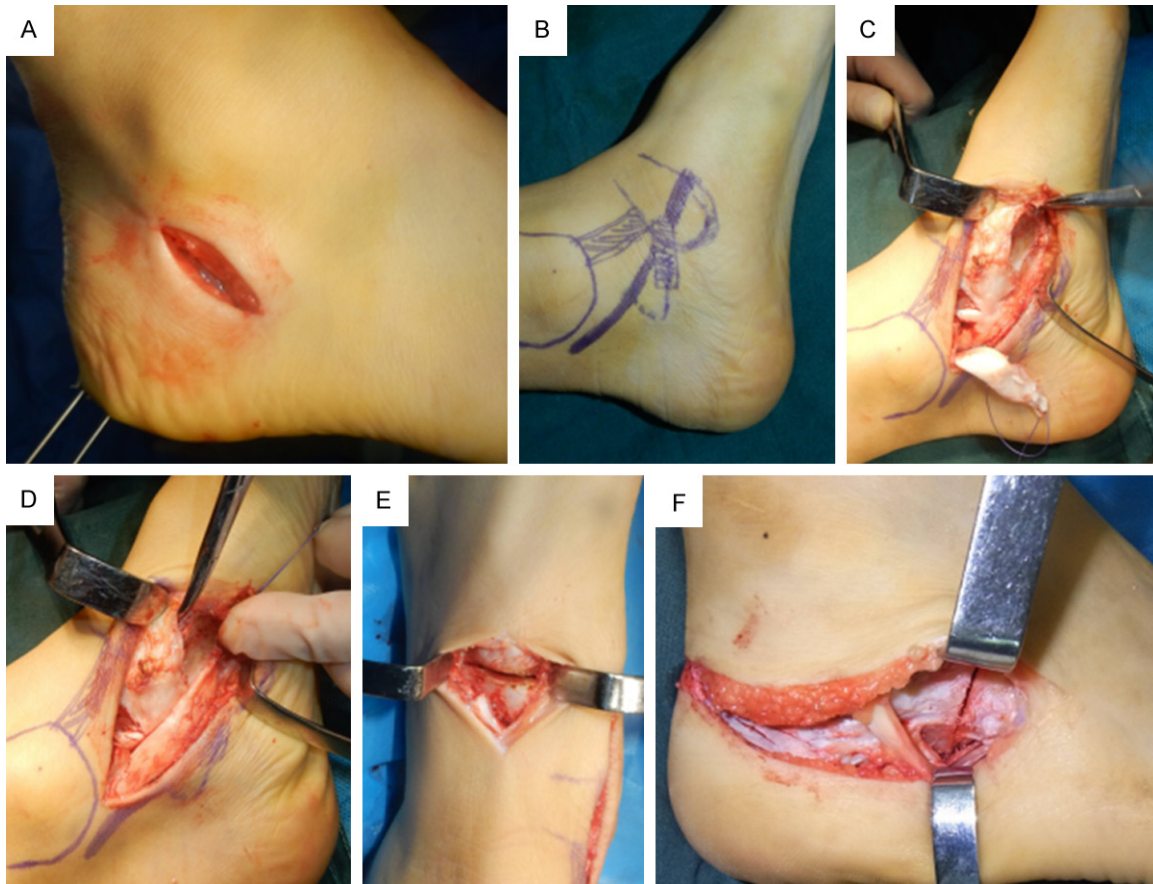
A detailed history was taken, and physical examination was undertaken before the surgery. Flexible flatfoot is characterized by a flat arch during weight bearing, but the arch recovers when the individual is sitting with the foot dangling. It was important to note the appearance of the forefoot when the heel was reduced to a neutral position during the examination. The Silfverskiöld test was used to identify the contracture of the gastrocnemius-soleus complex or Achilles tendon. Dorsiflexion of <math><10^\circ</math> indicated contracture of the Achilles tendon regardless of whether the knee was flexed or extended. If the dorsiflexion was >math>10^\circ</math> with the knee flexed but <math><10^\circ</math> with the knee extended, this implied contracture of the gastrocnemius complex. The Coleman block test or heel rise test was used to assess the hindfoot flexibility. The “too-many-toes” sign could show the extent of forefoot abduction.

Radiographic evaluation should include weight-bearing AP and lateral views of the foot, ankle AP view, and hindfoot alignment view. Advanced imaging is rarely indicated for the assessment of flatfoot deformity. Computed tomography and magnetic resonance imaging are usually employed to identify the extent and exact location of the coalition and soft tissue changes, respectively. The talonavicular coverage angle (TNCA) and talar-first metatarsal angle (T1MT) were assessed on foot AP views. The calcaneal pitch angle and Meary’s angle were recorded on foot lateral views. The calcaneus valgus angle (CVA) was assessed on hindfoot Saltzman views.

#### *Surgical technique*

Patients with a thigh tourniquet were placed in the supine position on an operating table under general anesthesia in addition to the regional nerve block. First, we performed gas-

## Combined procedures for children symptomatic flatfoot



**Figure 1.** Operative procedures of osteotomies combined with soft tissue surgery. We performed MDCO with lateral mini incision about 3-4 centimeters under peroneal tendon (A). Marked the medial anatomic symbol such as PTT, deltoid ligament and navicular tuberosity to make the surgical incision easily and clearly (B). Degenerative PTT was exposed and debrided. Removed the scar around the PTT insertion (C). Reattachment of PTT to the navicular tuberosity (D). Cotton osteotomy was performed in a patient with residual forefoot supination after restoring hindfoot alignment (E). The incision should be extended along the peroneal tendon because of the requirement for simultaneous performance of LCL and MDCO (F).

trocnemius recession or percutaneous Achilles lengthening according to the preoperative Silfverskiöld test. Subsequently, an incision was made below the tip of the fibula along the peroneal tendon. The sural nerve should be protected. After the subperiosteal dissection, a 45° osteotomy was performed with an oscillating saw. The posterior aspect of the calcaneus was translated medially at 0.5-1.0 cm to realign the hindfoot. A K-wire was used to fix the fragment temporarily. We raised the lower limb and evaluated the heel alignment under direct vision. This was determined exactly with an intraoperative Saltzman view. The medial displacement of calcaneal osteotomy (MDCO) was fixed with two 4.0 mm cannulated screws. If the epiphysis was open, a contoured mini-plate or K-wire was used for fixation (**Figure 1A**).

Following the MDCO procedure, midfoot abduction was evaluated clinically. Then, we extended the incision over the calcaneocuboid joint for the LCL procedure. The osteotomy cut was made 1 cm posterior to the calcaneocuboid joint. With the osteotomy distracted, the position of the talus relative to the navicular was checked clinically and radiographically. Once the position was corrected, an allograft of an appropriate size was used to maintain the reduction. Fixation was performed with a K-wire and a cannulated screw or plate (**Figure 1F**).

After completing the hindfoot osteotomy, medial soft tissue reconstruction was performed. A medial incision was made over the posterior tibial tendon (PTT). We debrided and repaired the mild or moderate PTT tear. If the PTT pre-

## Combined procedures for children symptomatic flatfoot

**Table 1.** Comparison of the functional outcomes and radiographic parameters between preoperative and final follow-up time

Parameters	Preoperative	Final follow-up	P-value
AOFAS scores	56.6±8.0	88.4±3.9	<0.001
FAOS (mean)	47.4±9.5	83.2±6.8	<0.001
Pain	48.2±5.4	84.3±8.7	<0.001
Symptoms	53.4±9.3	81.2±4.6	<0.001
Activities of daily living	32.4±10.5	82.6±7.5	<0.001
Sports activities	45.3±14.2	80.1±3.6	<0.001
Quality of life	57.6±7.9	87.6±9.5	<0.001
T1MT (°)	17.2±4.7	6.8±2.4	<0.001
TNCA (°)	19.4±4.4	7.8±2.2	<0.001
Calcaneal pitch angle (°)	16.9±5.2	21.1±4.3	0.014
Meary's angle (°)	14.2±3.6	4.3±2.4	<0.001
CVA (°)	15.9±3.0	5.4±2.1	<0.001

Note: AOFAS: American Orthopaedic Foot and Ankle Society ankle-hindfoot. Score, FAOS: Foot and Ankle Outcome Score, TNCA: talonavicular coverage angle, T1MT: talar-first metatarsal angle, CVA: calcaneus valgus angle.

sented a large, extensive and degenerative lesion, repair and flexor digitorum longus (FDL) transfer were performed. FDL was harvested from the Henry's knot and passed from the plantar to dorsal direction through a drill hole and sutured to itself in mild inversion. The deltoid and spring ligaments were evaluated. Imbrication suturing before FDL transfer was performed with appropriate tension. In children with a painful accessory navicular bone, which is more prevalent in this age group, we always try to use a screw for fixation of the accessory bone if the bone fragment is large enough. The excision of the entire accessory navicular bone and reattachment with the suture anchor are necessary if the bone is small (**Figure 1B-D**).

On completion of the soft tissue procedures, Cotton osteotomy was performed with residual forefoot supination. An incision was made over the medial cuneiform. Then, a laminar spreader was inserted, and a structural allograft was wedged into the osteotomy site after evaluation with intraoperative fluoroscopy. A plate was used to fix the osteotomy (**Figure 1E**).

### Postoperative management

The sutures were removed at 14 days postoperatively. A short cast was used, and weight bearing was avoided in the first six postoperative weeks. During this period, patients were

advised to undergo physical therapy for rehabilitation and to reduce the risk of deep vein thrombosis. Thereafter, patients were allowed partial weight bearing as tolerated. At eight weeks postoperatively, X-ray examination was performed to assess the consolidation of the osteotomies. Patients were allowed to perform full weight bearing after achieving complete bone healing. Outpatient visits at six months and one year postoperatively were required. The hardware was removed at one year postoperatively. The American Orthopedic Foot and Ankle Society (AOFAS) ankle-hindfoot (100 point scale) scores and Foot and Ankle Outcome Score (FAOS) (100 point scale) were employed to evaluate the clinical outcome. The FAOS consists of five separate subscales: pain, symptoms, activities of daily living, sports activities, and quality of

life. Each of these was scored separately on a scale from 0 (poor outcome) to 100 (best outcome) [12]. Radiographic parameters included TNCA, T1MT, calcaneal pitch angle, Meary's angle, and CVA. All data were assessed preoperatively and at the final follow-up visit. All the included parameters on the weight-bearing views were underwent by two observers independently.

At the final follow-up, patient's satisfaction rates were also assessed based on pain, shoe modification, daily and sports activity level, and the need for reoperation. Each patient was recorded by a grade of excellent, good, fair or poor (**Table 2**) [13].

### Statistical analysis

We used the software program SPSS 23.0 (IBM Corp., Chicago, IL, USA) to perform the statistical analysis. The continuous variables of normal distribution were expressed as mean ± standard deviation, the continuous variables of non-normal distribution were expressed as median (interquartile range), and the categorical variables were expressed as frequency (percentage [%]). The intraobserver and interobserver reliability were assessed by intraclass correlation coefficient (ICC) [14]. Correlations between 0.81-1 were regarded almost perfect, 0.61-0.8 were considered as substantial, while



## Combined procedures for children symptomatic flatfoot

**Table 2.** Patient's satisfaction rating system

Rating	Patient Conditions
Excellent	Painless foot and no footwear problems
Good	Painless foot and footwear modification
Fair	Mild foot pain with activity; no restriction of activity and plus or minus footwear modification
Poor	Moderate foot pain and restriction of activity and plus or minus footwear modification

0.41-0.6 were considered as moderate, 0.21-0.4 were regarded as fair and 0.1-0.2 were considered as slight agreement and less than 0.1 were regarded as poor agreement. For two comparisons, each value was compared by utilizing a t-test when each datum conformed to normal distribution, while the non-normally distributed continuous data were compared using non-parametric tests. The counting data were tested by utilizing a chi-square test. A value of  $P < 0.05$  was considered statistically significant.

### Results

#### *The general characteristics*

A total of 28 participants (47 feet) were included in this study. They included 16 boys (26 feet) and 12 girls (21 feet) with an average age of  $11.7 \pm 2.1$  (range 9-14) years at the time of surgery. The average follow-up time was  $29.7 \pm 8.6$  (range 20-45) months.

#### *The clinical efficacy*

All patients achieved bony unions within 10 weeks. The AOFAS scores improved significantly from  $56.6 \pm 8.0$  preoperatively to  $88.4 \pm 3.9$  at final follow-up ( $P < 0.001$ ). There was a statistically significant difference in the mean FAOS, which improved from  $47.4 \pm 9.5$  preoperatively to  $83.2 \pm 6.8$  at final follow-up ( $P < 0.001$ ). There were statistically significant differences between preoperative and postoperative scores in all FAOS subscales ( $P < 0.001$ ). Radiographic parameters, including TNCA ( $P < 0.001$ ) and T1MT ( $P < 0.001$ ) on foot AP views, calcaneal pitch angle ( $P = 0.014$ ) and Meary's angle ( $P < 0.001$ ) on foot lateral views, and CVA ( $P < 0.001$ ) on Saltzman views, had significantly improved at final follow-up. According to the categorical ratings, there were 23 feet with "excellent" results, 16 with "good" scores and 8 with "fair" results. All the patients and their

parents were satisfied with the functional outcomes (**Table 1; Figures 2-5**).

We demonstrated almost perfect intraobserver agreement for all radiographic parameters preoperatively (ICC range: 0.86-0.92) and final follow-up (ICC range: 0.83-0.94). Interobserver agreement ranged from 0.68 to 0.85 preoperatively and 0.64 to 0.82 at final follow-up, respectively. A summary of the reliability was presented in **Table 3**.

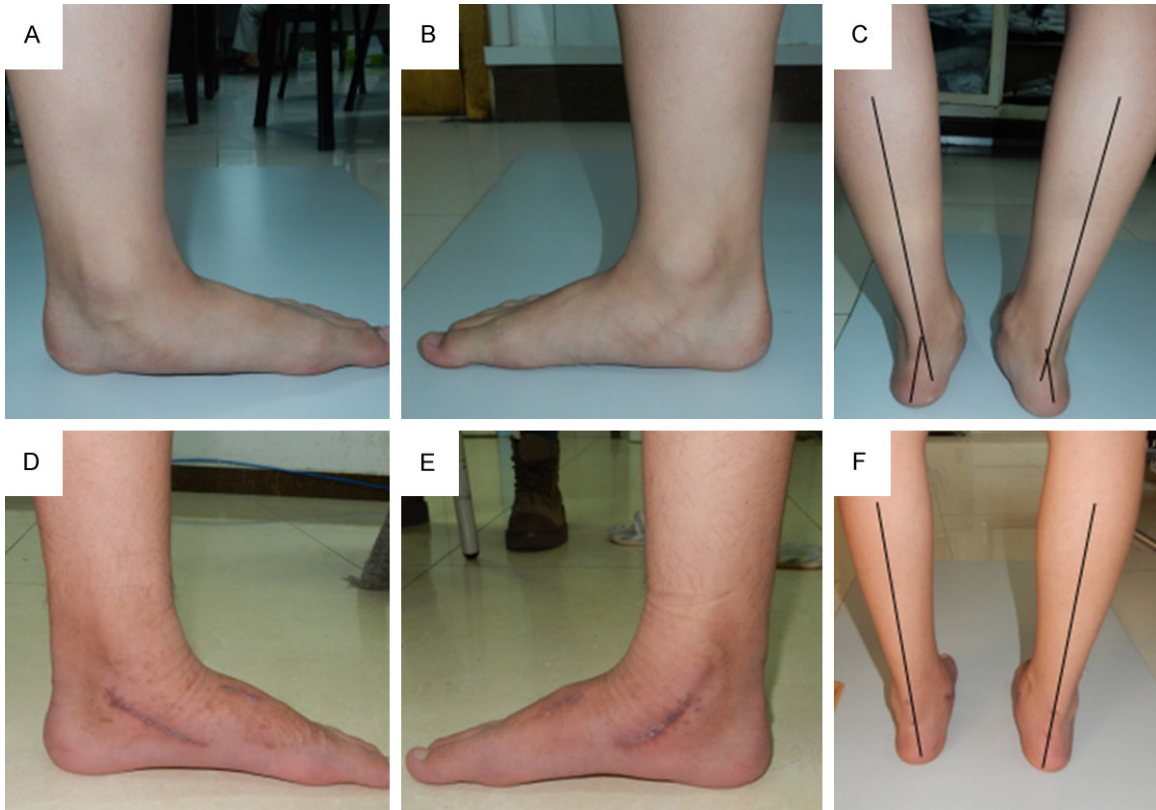
All the procedures performed in patients were as follows: gastrocnemius recession in 29 feet (61.7%), percutaneous Achilles lengthening in 18 feet (38.3%), LCL in 16 feet (34.0%), MDCO in 42 feet (89.4%), FDL transfer in five feet (10.6%), Cotton osteotomy in 18 feet (38.3%), spring ligament imbrication suturing in 20 feet (42.6%), resection of accessory navicular bone in 11 feet (23.4%), and fusion of accessory navicular bone in seven feet (14.9%).

Three patients had complications. One patient had sural nerve palsy; however, the symptoms disappeared after neurotrophic drug treatment for six months. One patient had residual pain in the medial foot, which was relieved by using a custom-made insole and gradually disappeared after three months. A patient with diabetes had superficial infection. With careful wound care and oral antibiotic treatment, the incision healed one month postoperatively. Nonunion and delayed union were not present in our cohort. All the patients returned to previous sporting activities without functional limitation and pain.

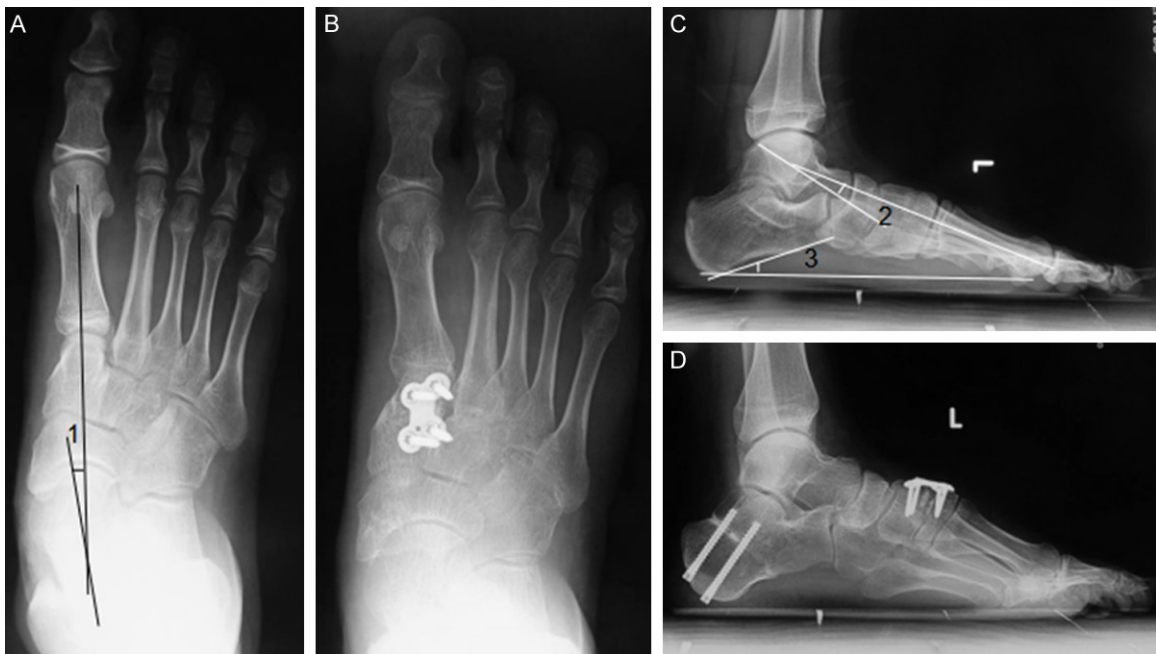### Discussion

Flexible flatfoot is a common disease in children. Most children experience spontaneous correction of the deformity or become asymptomatic. Conservative treatment is the first choice for flexible flatfoot in children. Surgery is indicated for patients with persistent pain

## Combined procedures for children symptomatic flatfoot



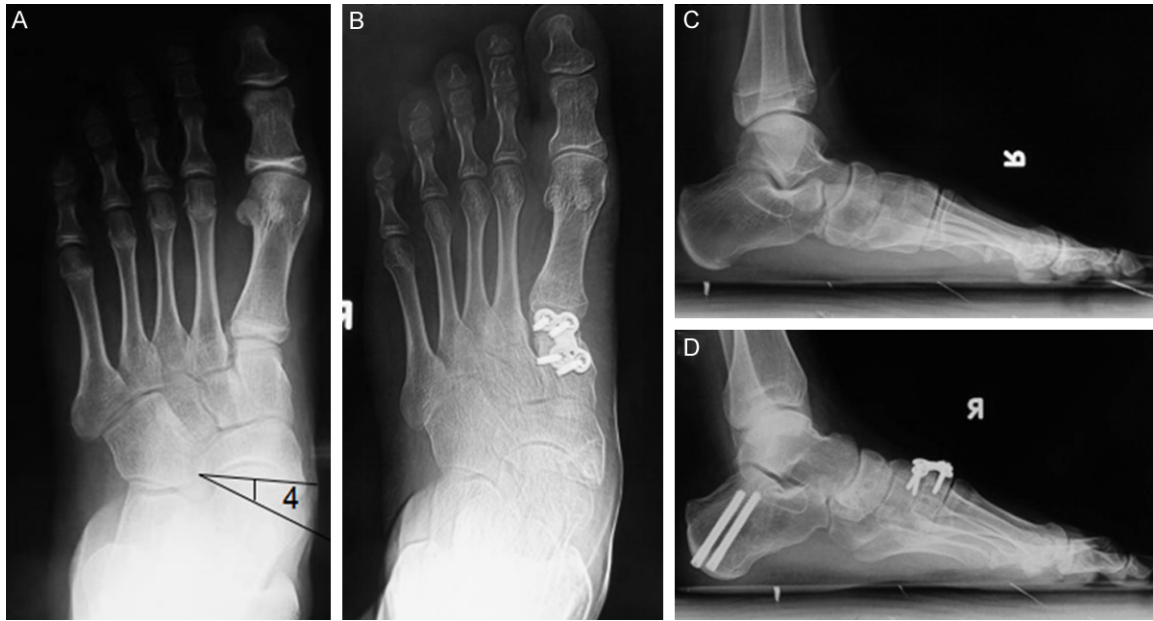**Figure 2.** A 12-year-old boy with bilateral flexible flatfoot deformity who underwent osteotomies (MDCO and Cotton osteotomy) combined with soft tissue procedures (percutaneous Achilles lengthening and repair of PTT and spring ligament) simultaneously. The bilateral medial longitudinal arch was diminished preoperatively (A, B). Meanwhile, The hindfoot valgus was apparent (C). Compared to the preoperative appearance, bilateral longitudinal arch was appeared (D, E) and hindfoot alignment was restored neutrally (F) at the final follow-up.



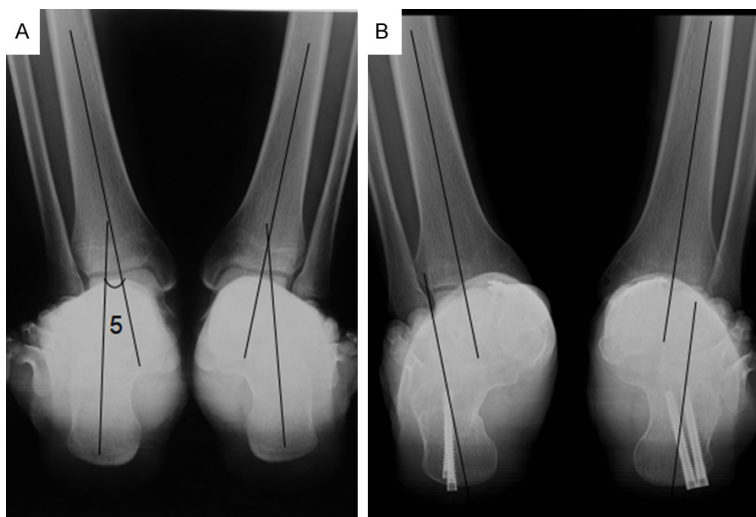
**Figure 3.** Preoperative and postoperative weight bearing AP and lateral views in the left foot. The radiograph demonstrated collapse of the arch with talar-first metatarsal angle (T1MA) of 7.9 degrees, Meary's angle of 12.7 degrees,

## Combined procedures for children symptomatic flatfoot

talo-navicular coverage angle of 19.3 degrees and calcaneal pitch angle of 16.7 degrees (A, C). The postoperative radiograph demonstrated restoration of the arch with T1MA of 4.2 degrees, Meary's angle of 3.4 degrees, talo-navicular coverage angle of 8.5 degrees and calcaneal pitch angle of 21.3 degrees (B, D). Numbers 1, 2, and 3 show the T1MA on the foot AP view, Meary's angle and the calcaneal pitch angle on the foot lateral views, respectively. The T1MA is defined as the angle created between the midline axis of first metatarsus and midline axis of talus. The Meary's angle is defined as the angle formed between the midline axis of first metatarsus and midline axis of talus on the foot lateral views. The calcaneal pitch angle is defined as the angle created between the floor and the line from the plantar apex of the calcaneal tubercle to the plantar apex of the calcaneus at the calcaneal cuboid joint.



**Figure 4.** Preoperative and postoperative weight bearing views in the right foot demonstrated that the forefoot and hindfoot alignment had been corrected. The radiograph demonstrated collapse of the arch with talar-first metatarsal angle (T1MA) of 12.7 degrees, Meary's angle of 18.9 degrees, talo-navicular coverage angle of 22.5 degrees and calcaneal pitch angle of 18.9 degrees (A, C). The postoperative radiograph demonstrated restoration of the arch with T1MA of 4.2 degrees, Meary's angle of 3.6 degrees, talo-navicular coverage angle of 6.5 degrees and calcaneal pitch angle of 29.1 degrees (B, D). Number 4 shows the talo-navicular coverage angle (TNCA) on the foot AP view. The TNCA is defined as the angle formed between the line connecting the edges of the articular surface of the talar head and another line connecting the edges of the articular surface of the navicular.



**Figure 5.** Preoperative Saltzman view (A) showed an obvious valgus in bilateral feet. The deformity was corrected after the combined surgery (B). Num-

ber 5 shows the calcaneus valgus angle (CVA) on a Saltzman view. The CVA is defined as the angle formed between the midline axis of tibia and the midline axis of calcaneus. The CVA of 15.7 degrees in left foot and 12.1 degrees in right foot preoperatively restored neutrally at the final follow-up.

despite conservative treatment [2-4, 15, 16]. The optimal surgical method and its timing remain controversial. The surgical plan for severe flexible flatfoot is complex, as we should consider correction of the hindfoot valgus, forefoot abduction, and longitudinal arch collapse. Arthrodesis

## Combined procedures for children symptomatic flatfoot

**Table 3.** Inter- and intraobserver reliability for radiographic measurement

	Preoperative (ICC)		Final follow-up (ICC)	
	Interobserver	Intraobserver	Interobserver	Intraobserver
T1MT	0.75	0.89	0.80	0.94
TNCA	0.82	0.86	0.74	0.86
Calcaneal pitch angle	0.78	0.91	0.82	0.91
Meary's angle	0.68	0.92	0.78	0.85
CVA	0.85	0.87	0.64	0.83

Note: ICC, intraclass correlation coefficient.

is not appropriate for children, especially with open epiphysis. Subtalar arthroereisis is recommended for children aged 8-12 years; however, it is not suitable for patients with severe deformities and those with a high risk of complication [8, 17]. Some researchers reported that osteotomies combined with additional soft tissue procedures used in adults can solve adolescent flexible flatfoot. The present study demonstrated that osteotomies with soft tissue reconstruction can achieve foot realignment and result in satisfactory clinical and radiographic outcomes in the children.

MDCO is commonly used in the correction of flexible flatfoot. If we only focus on the forefoot deformity and neglect the hindfoot valgus, the operation failure rate is high. MDCO can translate the weight-bearing alignment related to the lower limb and medialize the insertion of Achilles tendon to prevent subtalar joint degeneration and reduce the impingement of the lateral ankle. MDCO is a significant procedure when hindfoot valgus exists. In addition, MDCO can eliminate the negative deformity effects of Achilles tendon and improve the outcome of FDL transfer [7, 18]. In the present study, MDCO was performed in 42 feet (89.4%). The CVA evaluated on Saltzman views improved from 15.9° preoperatively to 5.4° postoperatively, indicating that the heel alignment almost normalized.

Some authors suggested that LCL or double calcaneal osteotomy was optimal for severe forefoot abduction deformity and better realigned the midfoot transverse plane deformities [5, 9, 19]. Furthermore, a cadaveric study reported that LCL can restore 60% of hindfoot valgus deformities associated with 100% forefoot abduction deformity [20]. In the current study, 16 feet underwent LCL and 13 feet underwent double calcaneal osteotomy. All the

patients achieved satisfactory outcomes except one patient, who had sural nerve palsy for six months. Therefore, it is critical to expose the sural nerve under direct visualization and protect it carefully during operation. The most common complication of LCL is calcaneocuboid subluxation and increased risk of calcaneocuboid arthritis [17], which did not occur in our patients. Patients with an average age of 11.7 years had strong growth potential to remodel the soft tissue balance. Furthermore, joint degenerative changes did not occur because of the short follow-up time.

Osteotomy and FDL transfer procedures are widely accepted in adults, and they have facilitated flatfoot reconstruction and resulted in excellent outcomes [21]. Accompanied by hindfoot osteotomies, soft tissue procedures maximally maintain the stability of the medial column and restore the foot arch. In this study, the decision to perform FDL transfer depended on the PTT characteristics. Although FDL transfer was not performed in patients with normal PTT characteristics, these patients still achieved hindfoot alignment. For cases with PTT accompanied by small or moderate-sized lesions, we debrided and sutured the PTT. If the PTT had a considerable tear and extensive degenerative changes, we repaired the PTT and performed FDL transfer to further strengthen the medial soft tissue [22]. Most children have a relatively healthy PTT compared to adults [4]. A previous biomechanical research study revealed that the spring ligament appeared to have similar importance to the PTT for supporting the medial arch [23]. Therefore, we evaluated the quality of the spring ligament and repaired it with imbrication suture.

Much controversy exists about the relationship between the accessory navicular bone and flatfoot. Senses et al. reported that there is no



clear association between the accessory navicular bone and flatfoot [24]. Jacobs et al. argued that the accessory navicular bone changed the insertion and biomechanical characteristics of the PTT. Symptomatic flatfoot can occur progressively [25]. Cha et al. prospectively compared the outcomes of simple excision and the Kidner procedure for painful accessory navicular bone and concluded that the two methods minimally restored the medial longitudinal arch [26]. Although still controversial, when a patient has symptomatic flatfoot with painful accessory navicular bone, overall foot alignment reconstruction should be performed rather than dealing with accessory bone alone. In addition, the large accessory navicular bone was fixed with a screw in this study, which differed from Cha's procedure [26]. We believe that bone-to-bone healing is easier than tendon-to-bone healing.

The Cotton osteotomy is an excellent adjunct to hindfoot correction procedures. When residual forefoot supination is present after restoring hindfoot alignment, Cotton osteotomy is indicated. Benthian et al. demonstrated that the LCL procedure may increase the lateral column pressure, resulting in an uncomfortable and painful foot [27]. Cotton osteotomy can reduce the risk of this complication [22]. In the current study, 18 feet underwent Cotton osteotomy, and the patients obtained excellent outcomes without complaints of lateral discomfort. These results may be due to the utilization of Cotton osteotomy and the strong adaptative ability in children.

Our study showed that children who underwent osteotomies combined with soft tissue procedures achieved promising clinical and radiographic outcomes. However, this study has several limitations. First, the patients underwent different combinations of corrective surgeries and had different preoperative conditions. It was therefore difficult to assess the efficacy of each procedure objectively. Furthermore, the sample size was small, which can result in a statistical bias and preclude the definitive conclusion of the operative procedures. Finally, we did not analyze the outcome until the epiphysis closed. As children grow older, the reconstruction results will perhaps change gradually. Therefore, a prospective randomized controlled study involving a larger number of patients and

longer follow-up time is warranted to determine the efficacy of osteotomies combined with soft tissue procedures in children.

### Conclusion

Osteotomies combined with soft tissue procedures is an effective strategy for flexible flatfoot deformity in children, as it results in favorable radiographic and functional outcomes.

### Acknowledgements

We appreciate the medical staff of the Surgical Department at Honghui Hospital where the operation was carried out. We would like to thank Editage ([www.editage.cn](http://www.editage.cn)) for English language editing. This study was funded by the current study received funding from Xi'an Science and technology plan project [no.sf1512 (2)]; Shaanxi science and technology research and development plan project (no.2016sf-333); Xi'an health bureau scientific research project (no.j201802027).

### Disclosure of conflict of interest

None.

### Abbreviations

AOFAS, American Orthopaedic Foot and Ankle Society ankle-hindfoot score; FAOS, Foot and Ankle Outcome Score; PTT, posterior tibial tendon; FDL, flexor digitorum longus; TNCA, talonavicular coverage angle; T1MT, talar-first metatarsal angle; CVA, calcaneus valgus angle; LCL, lateral column calcaneal lengthening; MDCO, medial displacement of calcaneal osteotomy; ICC, Intraclass Correlation Coefficient.

**Address correspondence to:** Yi Li, Department of Foot and Ankle Surgery, Honghui Hospital, Xi'an Jiaotong University, No.76 Nanguo Road, Beilin District, Xi'an 710054, China. Tel: +86-029-8780002; Fax: +86-029-87894724; E-mail: [liyicnas@163.com](mailto:liyicnas@163.com)

### References

- [1] Taspinar O, Kabayel DD, Ozdemir F, Tuna H, Keskin Y, Mercimek OB, Süt N, Yavuz S and Tuna F. Comparing the efficacy of exercise, internal and external shoe modification in pes planus: a clinical and pedobarographic study. J

## Combined procedures for children symptomatic flatfoot

- Back Musculoskelet Rehabil 2017; 30: 255-263.
- [2] Bouchard M and Mosca VS. Flatfoot deformity in children and adolescents: surgical indications and management. *J Am Acad Orthop Surg* 2014; 22: 623-32.
- [3] Bauer K, Mosca VS and Zions LE. What's new in pediatric flatfoot? *J Pediatr Orthop* 2016; 36: 865-9.
- [4] Yontar NS, Ogut T, Guven MF, Botanlioglu H, Kaynak G and Can A. Surgical treatment results for flexible flatfoot in adolescents. *Acta Orthop Traumatol Turc* 2016; 50: 655-9.
- [5] Mourkus H and Prem H. Double calcaneal osteotomy with minimally invasive surgery for the treatment of severe flexible flatfeet. *Int Orthop* 2018; 42: 2123-29.
- [6] Thévenin-Lemoine C and Khouri N. Surgical treatment of idiopathic pes planovalgus in paediatric patients. *Orthop Traumatol Surg Res* 2019; 105: S187-S198.
- [7] Kwon JY and Myerson MS. Management of the flexible flat foot in the child: a focus on the use of osteotomies for correction. *Foot Ankle Clin* 2010; 15: 309-22.
- [8] Mosca VS. Flexible flatfoot in children and adolescents. *J Child Orthop* 2010; 4: 107-21.
- [9] Xu Y, Cao YX, Li XC, Zhu Y and Xu XY. Double calcaneal osteotomy for severe adolescent flexible flatfoot reconstruction. *J Orthop Surg Res* 2017; 12: 153.
- [10] Sees JP and Miller F. Overview of foot deformity management in children with cerebral palsy. *J Child Orthop* 2013; 7: 373-7.
- [11] Ford SE and Scannell BP. Pediatric Flatfoot: Pearls and Pitfalls. *Foot Ankle Clin* 2017; 22: 643-56.
- [12] Conti MS, Garfinkel JH, Kunas GC, Deland JT and Ellis SJ. Postoperative medial cuneiform position correlation with patient-reported outcomes following cotton osteotomy for reconstruction of the stage II adult-acquired flatfoot deformity. *Foot Ankle Int* 2019; 40: 491-8.
- [13] Bonney G and Macnab I. Hallux valgus and hallux rigidus: a critical survey of operative results. *J Bone Joint Surg Br* 1952; 34-B: 366-85.
- [14] Landis JR and Koch GG. The measurement of observer agreement for categorical data. *Biometrics* 1977; 33: 159-174.
- [15] Harris EJ. The natural history and pathophysiology of flexible flatfoot. *Clin Podiatr Med Surg* 2010; 27: 1-23.
- [16] Moraleda L, Salcedo M, Bastrom TP, Wenger DR, Albiñana J and Mubarak SJ. Comparison of the calcaneo-cuboid-cuneiform osteotomies and the calcaneal lengthening osteotomy in the surgical treatment of symptomatic flexible flatfoot. *J Pediatr Orthop* 2012; 32: 821-29.
- [17] Suh DH, Park JH, Lee SH, Kim HJ, Park YH, Jang WY, Baek JH, Sung HJ and Choi GW. Lateral column lengthening versus subtalar arthroereisis for paediatric flatfeet: a systematic review. *Int Orthop* 2019; 43: 1179-92.
- [18] Chan JY, Williams BR, Nair P, Young E, Sofka C, Deland JT and Ellis SJ. The contribution of medializing calcaneal osteotomy on hindfoot alignment in the reconstruction of the stage II adult acquired flatfoot deformity. *Foot Ankle Int* 2013; 34: 159-66.
- [19] Lima TC and Volpon JB. Calcaneal lateral column lengthening osteotomy for symptomatic flexible flatfoot in children and adolescents: a systematic review. *Rev Col Bras Cir* 2018; 45: e1969.
- [20] Baxter JR, Demetracopoulos CA, Prado MP, Tharmviboonsri T and Deland JT. Lateral column lengthening corrects hindfoot valgus in a cadaveric flatfoot model. *Foot Ankle Int* 2015; 36: 705-9.
- [21] Conti MS, Garfinkel JH and Ellis SJ. Outcomes of reconstruction of the flexible adult-acquired flatfoot deformity. *Orthop Clin North Am* 2020; 51: 109-20.
- [22] Oh I, Williams BR, Ellis SJ, Kwon DJ and Deland JT. Reconstruction of the symptomatic idiopathic flatfoot in adolescents and young adults. *Foot Ankle Int* 2011; 32: 225-32.
- [23] Cifuentes-De la Portilla C, Larrainzar-Garjito R and Bayod J. Biomechanical stress analysis of the main soft tissues associated with the development of adult acquired flatfoot deformity. *Clin Biomech (Bristol, Avon)* 2019; 61: 163-71.
- [24] Senses I, Kiter E and Gunal I. Restoring the continuity of the tibialis posterior tendon in the treatment of symptomatic accessory navicular with flat feet. *J Orthop Sci* 2004; 9: 408-9.
- [25] Jacobs AM. Soft tissue procedures for the stabilization of medial arch pathology in the management of flexible flatfoot deformity. *Clin Podiatr Med Surg* 2007; 24: 657-65.
- [26] Cha SM, Shin HD, Kim KC and Lee JK. Simple excision vs the Kidner procedure for type 2 accessory navicular associated with flatfoot in pediatric population. *Foot Ankle Int* 2013; 34: 167-72.
- [27] Benthien RA, Parks BG, Guyton GP and Schon LC. Lateral column calcaneal lengthening, flexor digitorum longus transfer, and opening wedge medial cuneiform osteotomy for flexible flatfoot: a biomechanical study. *Foot Ankle Int* 2007; 28: 70-7.