

Original Article

Preservation of level IIb lymph nodes during supraomohyoid neck dissection for clinically node-negative oral squamous cell carcinoma

Hao Wu^{1,2,3}, Xue-Hui Sun², Wen-Ting Hu^{1,2}, Ling Zhang^{3,4,5}

¹Weifang Medical University, College of Stomatology, Weifang 261000, China; ²Department of Oral and Maxillofacial Surgery, Affiliated Hospital of Weifang Medical University, Weifang 261000, China; ³Department of Oral Maxillofacial-Head and Neck Oncology, Shanghai Ninth People's Hospital, College of Stomatology, Shanghai Jiao Tong University School of Medicine, Shanghai 200011, China; ⁴National Clinical Research Center for Oral Diseases, Shanghai 200011, China; ⁵Shanghai Key Laboratory of Stomatology & Shanghai Research Institute of Stomatology, Shanghai 200011, China

Received June 25, 2020; Accepted October 21, 2020; Epub December 15, 2020; Published December 30, 2020

Abstract: Purpose: To identify the significance of level IIb neck dissection for patients with clinically node-negative oral squamous cell carcinoma (OSCC). Methods: A retrospective study was conducted with 203 patients with OSCC with no palpable lymph nodes in neck admitted to the Department of Oral Maxillofacial-Head and Neck Oncology from January 2012 through December 2014. After the diagnostic evaluations, all patients underwent wide local dissection and periodic supraomohyoid neck dissection (SOHND). In total, 115 patients underwent SOHND with IIb lymph node dissection, and 88 patients underwent elective SOHND without IIb lymph node dissection. The incidence of level IIb lymph node metastasis was evaluated by pathological and immunohistological analyses. The results were analyzed with independent sample t-tests. The incidence of complications (mainly scapular syndrome) and IIb lymph node metastasis rate (mainly for the preserving IIb group) were analyzed. Results: In total, 7 (6.09%) of the 115 patients who underwent SOHND had level IIb lymph nodes involvement. After 3 years of follow-up, 83 (72.17%) patients who underwent SOHND had different degrees of scapular syndrome, and 27 (32.53%) patients who underwent SOHND improved through rehabilitation training but did not fully recover. Four (4.55%) patients who underwent elective SOHND (preserving IIb) developed scapular syndrome and recovered through rehabilitation after surgery. The 3-year overall survival rate of the 115 patients was 86.09%, and the 3-year overall survival rate of the 88 patients who underwent elective SOHND (preserving IIb) was 84.09%. There were no significant differences between the two groups ($P > 0.05$). Conclusion: Patients with clinically NO OSCC have a low rate of level IIb lymph node metastasis. Level IIb lymph nodes resection are not necessary during SOHND, which thereby protects the accessory nerve and its branches from damage and improves patient quality of life.

Keywords: Oral squamous cell carcinoma, supraomohyoid neck dissection, level IIb lymph nodes, accessory nerve, scapular syndrome

Introduction

Oral squamous cell carcinoma (OSCC) is the most common malignant tumor of the oral cavity, accounting for the vast majority (approximately 90%) of oral cancers [1]. OSCC metastasizes via lymphatic vessels to cervical lymph nodes [2, 3]. According to statistics, the incidence of clinical cervical lymph nodes metastases from OSCC can be as high as 40% [4]. For patients with no preoperative clinical or radiologic evidence of lymph node metastases,

the occurrence of occult regional lymph node metastases can be 15-34%, as revealed by pathohistological and molecular analyses [5]. Studies on the pattern of OSCC cervical lymph node metastasis showed that regional metastases are generally located in levels I-III, while the risk of level IV or V lymph node metastasis is extremely low [6]. Therefore, supraomohyoid neck dissection (SOHND) is now the most common surgical method for detecting occult metastatic cervical lymph nodes and treating clinically NO necks. SOHND resects the contents in

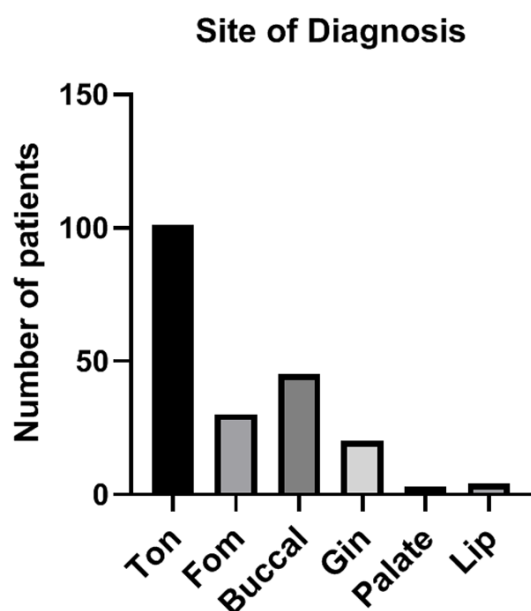


Figure 1. The primary sites of diagnosed oral squamous cell carcinoma in the 203 patients included in the current study.

levels I-III, to which oral cavity cancer most frequently metastases via lymphatic channels, but preserves functionally important anatomic structures, such as the sternocleidomastoid muscle, the internal jugular vein, and the accessory nerve [7, 8]. Many clinical studies have shown that SOHND and radical neck dissection (RND) have the same therapeutic effect in treating clinically NO necks in patients with OSCC [9, 10]. Therefore, SOHND, which refers to the resection of level I-III lymph nodes, has become the standard of elective treatment for clinically node-negative necks in patients with OSCC [11].

To avoid this complication, avoiding level IIb dissection has been proposed. Therefore, a few studies have tried to research the prevalence of lymph node metastases to level IIb in head and neck squamous cell carcinoma and have suggested that dissection of level IIb lymph nodes are not necessary [12-14]. Thus, the aim of this study was to identify the incidence of level IIb lymph node metastasis to help choose the appropriate surgical procedure and to evaluate the nodal recurrence in this area to determine whether this region could be excluded during SOHND for patients undergoing elective dissection for OSCC.

Patients and methods

Patients and clinical samples

Between January 2012 and December 2014, 203 previously untreated patients with OSCC with no palpable lymph nodes in the neck admitted to the Department of Oral Maxillofacial-Head and Neck Oncology, Ninth People's Hospital, Shanghai Jiao Tong University School of Medicine, were enrolled in this study. The inclusion criteria for this retrospective clinical study: Patients who was diagnosed as SCC by biopsy, with no palpable lymph nodes in neck; Patients with no preoperative clinical or radiologic evidence of lymph node metastases, and previously untreated; Patients who underwent unilateral or bilateral SOHND, which was performed immediately before the wide excision of primary tumor and performed in a standardized operation; Patients who received postoperative adjuvant therapy were not excluded, because adjuvant therapies had no negative effect on accessory nerve functions [15]. The patients with poor general condition, systemic disorders, distant metastases, neuromotor disorders, previous surgery or trauma history involved neck/arm/shoulder, and those who refused to join the study were excluded. Patients with inadequate data sets were excluded from the study.

The patients' ages ranged from 41 to 79 years (median, 59.7 years). There were 127 males and 76 females. The distribution of the primary lesions was as follows: tongue, 101 patients; buccal mucosa, 45 patients; floor of the mouth, 30 patients; gingiva, 20 patients; lip, 4 patients; and palate, 3 patients (**Figure 1**). The primary tumors were staged according to the 2002 classification of the American Joint Committee on Cancer: 128 tumors were staged as T1, and 75 tumors were staged as T2 (**Figure 2**). After completing diagnostic evaluations, all patients underwent surgery (wide primary tumor excision with SOHND or elective SOHND) (**Figure 3**). Of the 203 patients, 115 patients underwent IIb lymph node dissection (check preoperative CT of patients, **Figure 4**), and the remaining 88 patients did not undergo IIb lymph node dissection. Collecting photos of patients before and after surgery for comparison (**Figure 5**). The study was approved by the Medical Ethical Committee of the Ninth People's Hospital. Written informed

TNM staging results of the 203 patients

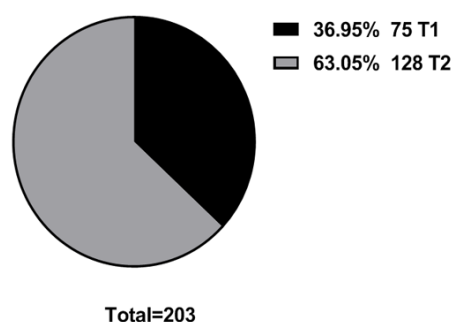


Figure 2. TNM staging results of the 203 patients with cNO oral squamous cell carcinoma.

consent was obtained from all participants involved in this study.

In the surgical specimen, the dissected lymphatic chains were separately labeled as levels I to III, with level II group being divided into IIa and IIb. The surgical specimens were sent to the Department of Pathology for analysis of the permanent section. The histopathological examination and immunohistochemistry analysis of the metastases included the number and location of the nodes containing metastatic disease, and whether the metastatic lymph nodes had the extracapsular spread.

The following data were obtained from patient charts: sex, age, primary lesion site, TNM status, operative procedure (especially type of neck dissection), incidence of scapular syndrome, and number and level of cervical lymph node metastases (**Table 1**).

Statistical analysis

The incidence of level IIb lymph node metastasis after SOHND (IIb dissection) or elective SOHND (preserving IIb), the incidence of level IIb lymph node recurrence, the status of scapular syndrome and the 3-year survival rate were evaluated. The follow-up period was 3 years, and the patients were followed up until death or until the time of the last known follow-up.

The results of the two patient groups were analyzed with independent sample t-tests using SPSS 22.0 statistical software. The analyzed indicators included complications (mainly scapular syndrome), and IIb lymph node metastasis rate (mainly for the preserving IIb group). There were no significant differences between the two groups ($P > 0.05$).

Results

A total of 115 patients underwent IIb lymph node dissection, and the remaining 88 patients did not undergo IIb lymph node dissection. Seven (6.09%) of the 115 patients who underwent SOHND had level IIb lymph node involvement. Of the 101 patients with primary tongue squamous cell carcinoma included in our study, 5 (4.95%) had IIb lymph nodes-metastases. To exclude the false-positive and false-negative problems of metastatic lymph nodes, HE staining and immunohistochemical staining (CK5/6, Ki67, P16, P40) were performed on the lymph nodes in this experimental study (**Figure 6**). The was found that the cells with specific staining were located in the cytoplasm and had obvious morphological differences from the peripheral lymphocytes. At the same time, the metastatic cancer cells in the positive control lymph nodes in each experiment had good color rendering, excluding false-negative results. Therefore, we believe that the results of this experiment are reliable.

After 3 years of follow-up, 83 (72.17%) patients who underwent SOHND had different degrees of scapular syndrome, and 27 (32.53%) of the 83 patients improved with rehabilitation training but still did not fully recover. Four (4.55%) patients who underwent elective SOHND (preserving IIb) developed scapular syndrome and recovered through postoperative rehabilitation. Five (5.68%) of the 88 patients who underwent elective SOHND (preserving IIb) had level IIb lymph node metastasis during postoperative follow-up, who were performed second operation. The shoulder function after the second operation was not included in the statistics. The 3-year overall survival rate of the 115 patients who underwent SOHND (IIb dissection) was 86.09%, and the 3-year overall survival rate of the 88 patients who underwent elective SOHND (preserving IIb) was 84.09% (**Table 2**). There were differences between the two groups in the postoperative shoulder dysfunction. There were no significant differences in 3-year survival rate between the two groups ($P > 0.05$).

Discussion

OSCC is the most common malignant disease of the oral cavity. Cervical lymph node metastasis is one of the most significant prognostic factors for survival in patients with OSCC. The surgical methods for managing neck lymph

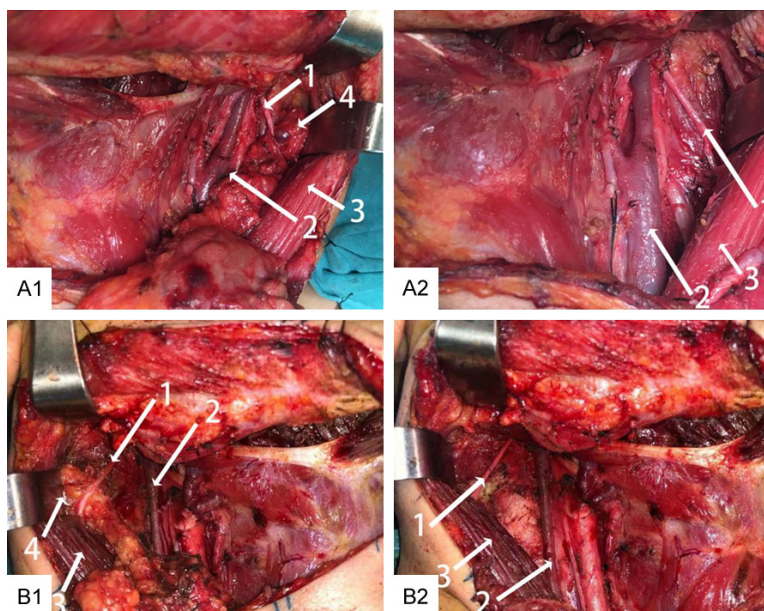


Figure 3. Intraoperative dissection photograph. A1, B1. Intraoperative view of SOHND showing the accessory nerve (1), internal jugular vein (2), sternocleidomastoid muscle (3) and level IIb lymph nodes (4). A2, B2. After the removal of specimens during SOHND, with the accessory nerve (1), internal jugular vein (2) and sternocleidomastoid muscle (3) shown.

node metastasis are classic RND, modified RND, and selective neck dissection. Feng and his colleagues reported that regional metastases of OSCC were generally located in levels I to III. In addition, they reported that the risk for level IV or V lymph node metastasis was extremely low [6]. Recent studies have shown that 91% of cervical node metastases from oral cavity cancers are concentrated in levels I to III, and if level IV is added to extensive SOHND, 96% of all lymph nodes metastases from oral cavity carcinoma would be covered by the dissection. The overall incidence of metastasis from OSCC to level V is as low as 3.3% [16]. Therefore, elective SOHND is becoming an effective management to clinically NO necks in patients with OSCC.

SOHND has become the standard treatment to avoid the functional complications that follow classic modified RND. However, there may be some postoperative complications after SOHND; one such complication is postoperative shoulder dysfunction. Patten and his colleague reported that almost all patients who underwent RND had shoulder pain and shoulder dysfunction due to the removal of the accessory nerve during surgery [17]. Krause and his colleagues found that 74% of patients who underwent RND had shoulder dysfunction,

and 44% of these patients showed loss of function. Compared with RND, modified RND and selective neck dissection, which theoretically preserve accessory nerve, do not or rarely cause shoulder dysfunction and pain. In fact, 31%-60% of the patients who underwent modified neck dissection (MND) have shoulder symptoms, and scapular syndrome still occurred after selective neck dissection [18]. Dijkstra and his colleagues found that the incidence of shoulder pain after RND was 79% and that the incidence of shoulder pain after modified RND was 65%, while the prevalence of posterior shoulder pain after selective neck dissection was 52% [19]. In selective neck dissections, shoulder dysfunction has been observed

in 21-60% of patients with preservation of accessory nerve [20]. Kraus and his colleagues reported that 50% of patients with preservation of accessory nerve experienced shoulder drop, and 30% of patients who underwent minimal accessory nerve anatomy had pain and shoulder dysfunction [21]. Those complications may be due to traction/electrical stimulation of the nerve during dissection of the level IIb lymph nodes, ischemia and neuropraxia of accessory nerve which caused by ligation of the occipital branch of the external carotid artery.

Therefore, dissection of level IIb lymph nodes in clinically NO OSCC patients is controversial. The controversy arises from the reported low risk for level IIb lymph node metastasis and potential shoulder disability. The incidence of occult metastasis in level IIb for clinical stage NO varies in the literature. In 2004, Lim and his colleagues had shown that 24 (32.4%) had positive lymph nodes in the 74 clinically NO patients, 4 of the 74 patients (5.4%) had level IIb lymph node involvement, and all patients had primary tumors located in the tongue. In the primary tongue tumor group (51 patients), the incidence of IIb metastasis was 7.8% (4 of 51). The authors concluded that level IIb lymph node metastasis was rare and that nodal

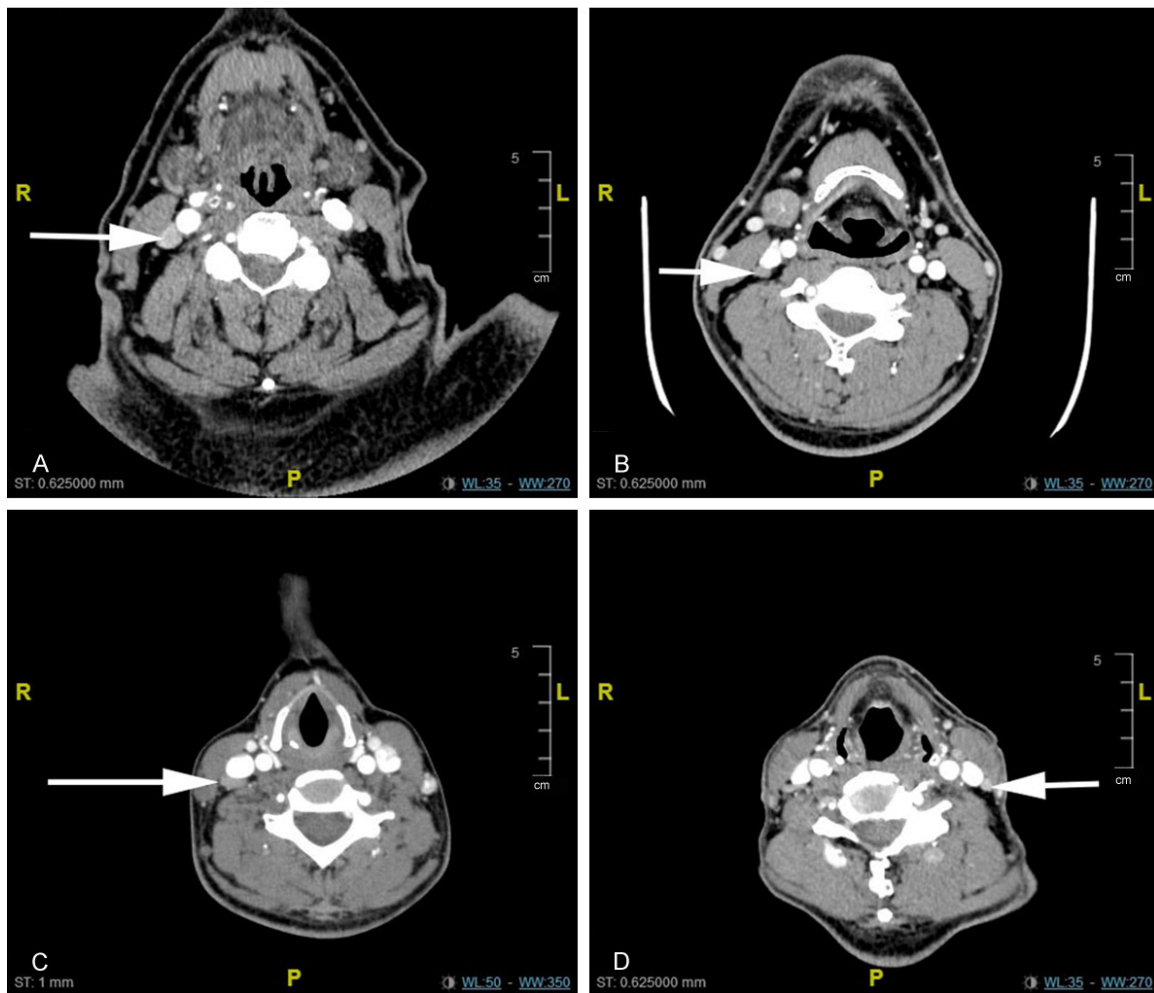


Figure 4. (A-D) preoperative CT of patients with positive IIb lymph nodes. Arrows indicated positive lymph nodes of level IIb.

recurrence in this area was infrequent after SOHND for OSCC. Consequently, they recommended that level IIb could potentially be preserved in elective SOHND patients with OSCC [22]. Kraus and his colleagues reported zero patients with metastasis at this level out of 39 OSCC patients who underwent selective neck dissection in a prospective study; Chiesa and his colleagues reported only 1 patient with level IIb lymph node metastasis out of 11 OSCC patients (9.1%); Villaret and his colleagues reported that the oral cavity cancer has the higher incidence of level IIb metastasis (10%) than other head and neck squamous cell carcinomas, but these metastases were only found in 2% of clinically NO patients; thus, the authors concluded that level IIb dissections could be avoided in clinically NO patients with OSCC [21, 23, 24]. Elsheikh and his colleagues

found the incidence of level IIb lymph node metastasis in study of 48 patients with OSCC and NO necks who underwent SOHND [25]. In a recent study, Lea and his colleagues observed that the incidence of level IIb nodal metastasis in the literature ranged from 0% to 10.4% [14]. Based on a meta-analysis, de Vicente and his colleagues concluded that the prevalence of level IIb lymph node metastasis in previously untreated OSCC patients with clinically node-negative is 6.0% [26].

To sensitively and specifically detect tumor cells in the lymph nodes, histopathological examinations and immunohistochemical analyses were applied. The keratin immunohistochemical staining technique surpasses conventional hematoxylin and eosin (HE) staining techniques in the detection rate of microme-



Figure 5. Preoperative and postoperative shoulder functional status of patients. A1. Preoperative picture of patients who underwent elective SOHND (preserving IIb); A2. Shoulder function barrier free after elective SOHND (preserving IIb); B1, C1. Preoperative picture of patients who underwent SOHND (IIb dissection); B2, C2. Accessory nerve injury during SOHND and shoulder function impairment after operation.

tastasis. Because of the absence of keratin in lymphoid tissues, the unique component of the epithelial cell can be used as an antibody for squamous cell carcinoma markers, and tissue sections can be stained to find micrometastases in level IIb lymph nodes. False-positive and false-negative tests are inevitable in diagnosis of micrometastasis. In this experimental study, false positive results are excluded mainly through the following points: (1) No specific staining was observed in the negative control lymph nodes. (2) Cells with specific staining were located in the cytoplasm and had obvious morphological differences with the peripheral lymphocytes. (3) Other impurities were excluded, such as the edge of the dry sheet caused by nonspecific coloring. (4) Pathologists read the slides and checked the

original HE staining sections of the same lymph nodes for diagnosis. At the same time, the metastatic cancer cells in the positive control lymph nodes in each experiment had good color rendering, excluding false-negative results. Therefore, we believe that the results of this experiment are reliable.

In a study that detected cervical lymph node metastasis with keratin immunohistochemistry, Kwon and his colleagues found micrometastases in 13 (18.8%) of 69 patients with head and neck squamous cell carcinoma [27]. In our series, the incidence of level IIb lymph node metastasis after SOHND (IIb dissection) or elective SOHND (preserving IIb) was evaluated by pathologic examination and immunohistochemistry analysis. Therefore, we found the incidence of 6.09% for level IIb micrometasta-

Table 1. Demographic data of 203 patients with clinically NO OSCC

Number (%)	
Sex	
Male	127 (63%)
Female	76 (37%)
Age	
Minimum	41 years
Maximum	79 years
Mean	59.7 years
Primary site of diagnosis	
Tongue	101 (49.75%)
Floor of mouth	30 (14.78%)
Buccal mucosa	45 (22.17%)
Gingiva	20 (9.85%)
Upper Lip	2 (0.99%)
Lower Lip	2 (0.99%)
Hard Palate	2 (0.99%)
Soft Palate	1 (0.49%)
Staging of the primary	
T1	128 (63.05%)
T2	75 (36.95%)
Surgery	
Excision of primary lesion and ESOHND (level IIb preserving)	88 (43.34%)
Excision of primary lesion and SOHND (level IIb dissection)	115 (56.65%)

OSCC, oral squamous cell carcinoma; SOHND, supraomohyoid neck dissection; ESOHND, elective supraomohyoid neck dissection.

ses with molecular studies in 115 patients with clinically node-negative OSCC who underwent SOHND. Compared with the current literature, this is a low prevalence. Of the 101 patients with primary tongue squamous cell carcinoma included in our study, 5 (4.95%) had IIb lymph node metastasis. Maher and his colleague found level IIb lymph nodes metastases in 4 (5.6%) of 71 patients with clinically NOOSCC. In patients with level IIb metastases, 3 patients with tongue carcinomas, and the other with retromolar trigone cancer [28]. Pantvaidya and his colleagues described similar findings: patients with tongue cancers (5%) and retromolar trigone cancer (6.2%) had the higher incidence of level IIb metastasis [16]. Chheda and his colleagues analyzed a series that included 210 patients with oral cancers, of whom 50 underwent SOHND, 40 underwent extended SOHND and 120 underwent MND. Among the 210 patients who underwent neck dissections, only 2 patients showed evidence of metastasis in level IIb (< 1%) [29]. Compared with the current literature, this is a low prevalence, and we did

not find that the T stage tumor and location within the oral cavity are not reliable indicators of level IIb metastasis. One reason may be that approximately 49.75% of patients had tongue cancer, and all patients had T1 or T2 stage disease. Therefore, a limitation of this study could be the limited statistical power due to the lack of sample size and inclusion of multiple sites, which requires the confirmation of results in further multicentric trial to validate the present results in different settings and different primary sites. In the future, we will continue to improve and update the research data to provide a more reliable scientific basis for guiding the selection of surgical methods for patients with cNO oral squamous cell carcinoma.

Conclusion

The incidence of level IIb lymph node metastasis in patients with clinically NO OSCC is low. Level IIb lymph node dissection is not necessary during SOHND, which thereby protects the accessory nerve and its branches from damage and improves patient quality of life.

Acknowledgements

This research was supported by the National Natural Science Foundation of China (No. 81-771127).

Disclosure of conflict of interest

None.

Address correspondence to: Wen-Ting Hu, Department of Oral and Maxillofacial Surgery, Affiliated Hospital of Weifang Medical University, No. 2428, Yu He Road, Weifang 261000, China. E-mail: wentinghu@163.com; Ling Zhang, Department of Oral

Preservation of level IIb lymph nodes during supraomohyoid neck dissection

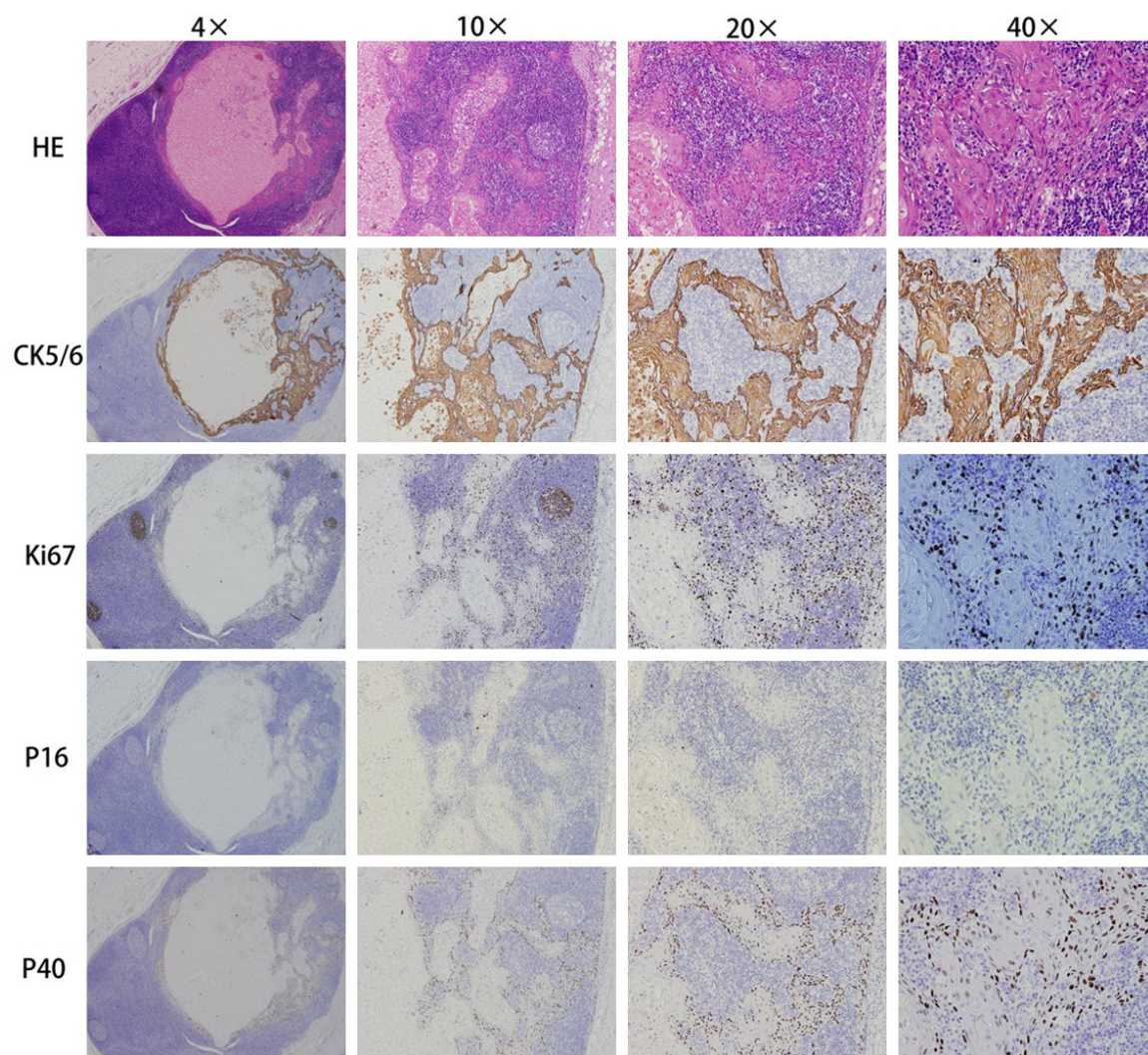


Figure 6. HE staining and immunohistochemical staining results of positive lymph nodes. Metastases detected by HE staining, keratin immunohistochemical staining with CK5/6, proliferation markers Ki67, cancer suppressor gene P16 and cancer suppressor gene P40 (4×, 10×, 20×, 40×).

Table 2. Compare the effect of SOHND and ESOHND

	SOHND (level IIb dissection)	ESOHND (level IIb preserving)	P
Postoperative shoulder dysfunction	83 (72.17%)	4 (4.55%)	P < 0.05
The 3-year overall survival rate	86.09%	84.09%	P > 0.05
Level IIb lymph node metastasis rate	7 (6.09%)	5 (5.68%)	P > 0.05

P < 0.05, significant differences between the two groups; P > 0.05, no significant differences between the two groups.

Maxillofacial-Head and Neck Oncology, Ninth People's Hospital Affiliated to Shanghai Jiao Tong University School of Medicine, No. 639, Zhi Zao Ju Road, Shanghai 200011, China. E-mail: topgun11-28@126.com

References

[1] Siegel RL, Miller KD and Jemal A. Cancer statistics, 2019. *CA Cancer J Clin* 2019; 69: 7-34.

[2] Kumar T and Patel MD. Pattern of lymphatic metastasis in relation to the depth of tumor in oral tongue cancers: a clinico pathological correlation. *Indian J Otolaryngol Head Neck Surg* 2013; 65: 59-63.

[3] Massano J, Regateiro FS, Januario G and Ferreira A. Oral squamous cell carcinoma: review of prognostic and predictive factors. *Oral Surg Oral Med Oral Pathol Oral Radiol Endod* 2006; 102: 67-76.

- [4] Okura M, Aikawa T, Sawai NY, Iida S and Kogo M. Decision analysis and treatment threshold in a management for the NO neck of the oral cavity carcinoma. *Oral Oncol* 2009; 45: 908-911.
- [5] Noguti J, De Moura CF, De Jesus GP, Da Silva VH, Hossaka TA, Oshima CT and Ribeiro DA. Metastasis from oral cancer: an overview. *Cancer Genomics Proteomics* 2012; 9: 329-335.
- [6] Feng Z, Li JN, Niu LX and Guo CB. Supraomohyoid neck dissection in the management of oral squamous cell carcinoma: special consideration for skip metastases at level IV or V. *J Oral Maxillofac Surg* 2014; 72: 1203-1211.
- [7] Carlson ER, Cheung A, Smith B and Pfohl C. Neck dissections for oral/head and neck cancer: 1906-2006. *J Oral Maxillofac Surg* 2006; 64: 4-11.
- [8] Yu S, Li J, Li Z, Zhang W and Zhao J. Efficacy of supraomohyoid neck dissection in patients with oral squamous cell carcinoma and negative neck. *Am J Surg* 2006; 191: 94-99.
- [9] Majoufre C, Faucher A, Laroche C, De Bonfils C, Siberchicot F, Renaud-Salis JL and Pinsolle J. Supraomohyoid neck dissection in cancer of the oral cavity. *Am J Surg* 1999; 178: 73-77.
- [10] Hosal AS, Carrau RL, Johnson JT and Myers EN. Selective neck dissection in the management of the clinically node-negative neck. *Laryngoscope* 2000; 110: 2037-2040.
- [11] Kerrebijn JD, Freeman JL, Irish JC, Witterick IJ, Brown DH, Rotstein LE and Gullane PJ. Supraomohyoid neck dissection. Is it diagnostic or therapeutic? *Head Neck* 1999; 21: 39-42.
- [12] Cheng PT, Hao SP, Lin YH and Yeh AR. Objective comparison of shoulder dysfunction after three neck dissection techniques. *Ann Otol Rhinol Laryngol* 2000; 109: 761-766.
- [13] Kou Y, Zhao T, Huang S, Liu J, Duan W, Wang Y, Wang Z, Li D, Ning C and Sun C. Cervical level IIb metastases in squamous cell carcinoma of the oral cavity: a systematic review and meta-analysis. *Onco Targets Ther* 2017; 10: 4475-4483.
- [14] Lea J, Bachar G, Sawka AM, Lakra DC, Gilbert RW, Irish JC, Brown DH, Gullane PJ and Goldstein DP. Metastases to level IIb in squamous cell carcinoma of the oral cavity: a systematic review and meta-analysis. *Head Neck* 2010; 32: 184-190.
- [15] Carenfelt C and Eliasson K. Occurrence, duration and prognosis of unexpected accessory nerve paresis in radical neck dissection. *Acta Otolaryngol* 1980; 90: 470-473.
- [16] Pantvaidya GH, Pal P, Vaidya AD, Pai PS and D'Cruz AK. Prospective study of 583 neck dissections in oral cancers: implications for clinical practice. *Head Neck* 2014; 36: 1503-1507.
- [17] Patten C and Hillel AD. The 11th nerve syndrome. Accessory nerve palsy or adhesive capsulitis? *Arch Otolaryngol Head Neck Surg* 1993; 119: 215-220.
- [18] Krause HR, Bremerich A and Herrmann M. The innervation of the trapezius muscle in connection with radical neck-dissection. An anatomical study. *J Craniomaxillofac Surg* 1991; 19: 87-89.
- [19] Dijkstra PU, van Wilgen PC, Buijs RP, Brendeke W, de Goede CJ, Kerst A, Koolstra M, Marinus J, Schoppink EM, Stuiver MM, van de Velde CF and Roodenburg JL. Incidence of shoulder pain after neck dissection: a clinical explorative study for risk factors. *Head Neck* 2001; 23: 947-953.
- [20] Short SO, Kaplan JN, Laramore GE and Cummings CW. Shoulder pain and function after neck dissection with or without preservation of the spinal accessory nerve. *Am J Surg* 1984; 148: 478-482.
- [21] Kraus DH, Rosenberg DB, Davidson BJ, Shaha AR, Spiro RH, Strong EW, Schantz SP and Shah JP. Supraspinal accessory lymph node metastases in supraomohyoid neck dissection. *Am J Surg* 1996; 172: 646-649.
- [22] Lim YC, Song MH, Kim SC, Kim KM and Choi EC. Preserving level IIb lymph nodes in elective supraomohyoid neck dissection for oral cavity squamous cell carcinoma. *Arch Otolaryngol Head Neck Surg* 2004; 130: 1088-1091.
- [23] Chiesa F, Mauri S, Grana C, Tradati N, Calabrese L, Ansarin M, Mazzarol G and Paganelli G. Is there a role for sentinel node biopsy in early NO tongue tumors? *Surgery* 2000; 128: 16-21.
- [24] Villaret AB, Piazza C, Peretti G, Calabrese L, Ansarin M, Chiesa F, Pellini R, Spriano G and Nicolai P. Multicentric prospective study on the prevalence of sublevel IIb metastases in head and neck cancer. *Arch Otolaryngol Head Neck Surg* 2007; 133: 897-903.
- [25] Elsheikh MN, Mahfouz ME and Elsheikh E. Level IIb lymph nodes metastasis in elective supraomohyoid neck dissection for oral cavity squamous cell carcinoma: a molecular-based study. *Laryngoscope* 2005; 115: 1636-1640.
- [26] de Vicente JC, Rodriguez-Santamarta T, Pena I, Villalain L, Fernandez-Valle A and Gonzalez-Garcia M. Relevance of level IIb neck dissection in oral squamous cell carcinoma. *Med Oral Patol Oral Cir Bucal* 2015; 20: e547-553.
- [27] Kwon SY, Kim HJ, Woo JS, Jung KY and Kim I. The usefulness of cytokeratin immunohistochemistry in detection of lymph node micro-metastasis in neck dissection specimens.

Preservation of level IIb lymph nodes during supraomohyoid neck dissection

- Otolaryngol Head Neck Surg 2004; 131: 300-306.
- [28] Maher NG and Hoffman GR. Elective neck dissection for primary oral cavity squamous cell carcinoma involving the tongue should include sublevel IIb. J Oral Maxillofac Surg 2014; 72: 2333-2343.
- [29] Chheda YP, Pillai SK, Parikh DG, Dipayan N, Shah SV and Alaknanda G. A prospective study of level IIb nodal metastasis (supraretrospinal) in clinically no oral squamous cell carcinoma in Indian population. Indian J Surg Oncol 2017; 8: 105-108.