

Original Article

Comparison of changes in wound healing parameters following treatment with three topical wound care products using a laser wound model

Qing Xu^{1,2,3}, Lingyue Shen^{1,2,3}, Xia Yang^{1,2,3}, Hao Peng^{1,2,3}, Ming Liu^{1,2,3}

¹Department of Oral and Maxillofacial-Head Neck Oncology, Shanghai Ninth People's Hospital, College of Stomatology, Shanghai Jiao Tong University School of Medicine, Shanghai 200011, China; ²National Clinical Research Center for Oral Diseases, Shanghai 200011, China; ³Shanghai Key Laboratory of Stomatology & Shanghai Research Institute of Stomatology, Shanghai 200011, China

Received November 16, 2020; Accepted January 7, 2021; Epub April 15, 2021; Published April 30, 2021

Abstract: Purpose: This study intended to analyze the differences in the efficacy of three topical wound care products on wound healing in patients undergoing surgery under the laser wound model. Method: A total of 130 patients in the department of dermatology enrolled for retrospective analysis. These patients were divided into group A (n=43, Zihua Shaoshang Ruangao), group B (n=43, Shengji Yuhong Gao), and group C (n=44, Shirun Shaoshang Gao), respectively, according to the type of wound care product administrated. The efficacy was compared during one month of treatment. Results: There was little difference among groups A, B, and C in VAS score, FGF, EGF, and concentration of substance P (SP) at 1, 3, 5, 7, and 10 days after surgery ($P>0.05$), and a significant difference in these parameters among different time points was observed for intra-group comparison ($P<0.05$). There was no significant difference in the symptom scores at 1, 5, 10, 15, 20, 25, and 30 days after surgery among the three groups ($P>0.05$), while there was statistically significant difference at different time points in the same group ($P<0.05$). The wound healing rates at 10, 20, and 30 days after surgery were 25.58%, 65.12%, and 95.35% in group A, 20.93%, 67.44%, and 100.00% in group B and 25.00%, 59.09%, and 97.73% in group C respectively ($P>0.05$). The patients' satisfaction rate towards the appearance was 95.35% in group A, 97.67% in group B, and 97.73% in group C ($P>0.05$). Conclusion: The three kinds of wound care products, namely Zihua Shaoshang Ruangao, Shengji Yuhong Gao and Shirun Shaoshang Gao, exhibited good efficacy on the wound care of patients after dermatologic surgery. The wounds could be improved quickly, and patients were highly satisfied with the new appearance of the wound. Clinically, wound care products can be selected according to the stock of products in the hospital and patients' preferences.

Keywords: Laser wound model, dermatology surgery, wound, nursing ointment, nursing, healing parameters

Introduction

With the advancement of medical technology, medical cosmetology or aesthetic medicine is rapidly becoming the pursuit of people. More skin diseases can be improved by surgery. Dermatology surgery under the laser wound model is an advanced surgical method for the preparation of wound models by laser, and performing surgical operations after preparation of wounds can improve the accuracy of surgical operations, reduce the trauma, and reduce the difficulty of recovery [1].

However, due to the invasive nature of surgery, there are still wounds that need to be repaired

after surgery. People are more aesthetically sensitive. As a result, they have high expectations for wound recovery after skin surgery. For patients undergoing surgery under the laser wound model, wound healing ointment is often prescribed to promote wound healing after surgery. There are many clinical options. This study mainly focused on Zihua Shaoshang Ruangao, Shengji Yuhong Gao and Shirun Shaoshang Gao. These three nourishing ointments are all traditional Chinese medicine preparations. Among them, Shaoshang Ruangao is mainly composed of pepper, *Rehmannia glutinosa*, comfrey, borneol, coptis chinensis, etc., which can relieve pain and reduce inflammation, clear heat and resolve toxin, cool blood and remove

Comparison of changes in wound healing parameters

blood stasis, remove necrotic tissues and promote granulation [2]. A comparative study on the efficacy of Zihua Shaoshang Ruangao Vs. Zinc Oxide ointment found that the former was significantly more effective [3]. The ingredients of Shengji Yuhong Gao include ashwax, sesame oil, *Angelica sinensis*, *Angelica dahurica*, *Draconis Sanguis*, comfrey, Mercurous Chloride, licorice, etc., which can play a role in regenerating the muscle and moisturizing the skin, removing necrotic tissues and invigorating blood, relieving pain and detoxifying toxins [4]. In a previous study, one group of patients chose potassium permanganate solution to fumigate the wound, and the other group of patients chose Shengji Yuhong Gao to heal the wound, and the results showed that the pain level and wound healing rate of the latter group were higher than the former group on the 5th and 10th day after treatment [5]. The main components of Shirun Shaoshang Gao are *Phellodendron Bark*, *Scutellaria baicalensis*, Earthworm, *Rhizoma Polygonati*, and Opium Husk, which can exert the effect of removing necrotic tissues and promoting granulation, purging fire for removing toxin, and clearing the damp-heat [6]. A study compared the difference in the effect of doxycycline and Shirun Shaoshang Gao, and the results showed a significant difference in the total effectiveness rate of wound healing between the two groups (90.90% vs 75.51%) [7].

However, most of these three ointments were compared with Western medicines in previous studies but the difference in efficacy among these three products was unclear. In this study, 130 dermatological patients were enrolled as subjects, and their different in efficacy were compared.

Materials and methods

Information

A total of 130 patients underwent surgical treatment under the laser wound model at the Dermatology Department of our hospital were enrolled and divided into group A (n=43, Zihua Shaoshang Ruangao), group B (n=43, Shengji Yuhong Gao), and group C (n=44, Shirun Shaoshang Gao), respectively, according to the type of wound care product administrated. Inclusion criteria: patients who underwent surgical treatment under the laser wound model,

expected to be hospitalized in the postoperative period and were administrated wound care products to promote healing; and patients who were aware of the study procedures and signed a consent form were included. This study was approved by the Ethics Committee. Exclusion criteria: patients who received other modalities to promote wound healing; and patients who combined with other kinds of untreated skin diseases, cardiovascular disease, hepatic and renal dysfunction, and coagulopathy were excluded.

Methods

Group A received Zihua ShaoShang Gao for postoperative wound care. First, sterile saline water was used to irrigate wounds. The ointment was applied once daily at 2 mm thickness and 1 cm beyond the edge of the wound. After the completion of application, a self-adhesive film dressing was used to cover the wound for protection, and wound dressings should be changed once every day. During the dressing change, the wound should be checked, and if there was any secretion, a sterile syringe should be used to extract the secretion and sterile saline solution should be used to clean the wound before applying ointment.

In groups B and C, Shengjiyuhong Gao and Shirun shaoshang Gao were applied, respectively. The procedures and dosing were the same as in group A. All three groups were treated for 3 courses, with 10 days as one course.

Outcomes measurement

Wound pain level: patients' wound pain level was assessed by visual analogue scale (VAS) [8] at 1, 3, 5, 7, and 10 days after surgery, respectively.

Symptom scores: Symptoms of exudation, edema, pain, and skin breakage were scored on a 0-3 scale, with 0 standing for no symptoms, 1 for mild symptoms, 2 for moderate symptoms, and 3 for severe symptoms. The final scores ranged 0-12. Evaluations were performed once at 1, 5, 10, 15, 20, 25, and 30 days after surgery, respectively.

Wound healing parameters: Fibroblast growth factor (FGF), epidermal growth factor (EGF), substance P concentration, FGF and EGF at 1,

Comparison of changes in wound healing parameters

Table 1. Comparison of general information among the three groups ($\bar{x} \pm s$)/[n (%)]

Baseline data		Group A (n=43)	Group B (n=43)	Group C (n=44)	t/X ²	P
Gender	Male	16 (37.21)	14 (32.56)	17 (38.64)	1.076	0.824
	Female	27 (62.79)	29 (67.44)	27 (61.36)		
Age (years)		37.85±15.43	39.15±14.72	17.98±14.88	0.722	0.315
Course of disease		1.76±1.05	1.81±1.04	1.71±1.21	0.629	0.411
Body weight (kg)		62.43±8.76	60.71±7.94	62.45±7.88	0.383	0.198
BMI (kg/m ²)		22.63±1.12	21.76±1.24	22.13±1.16	1.007	0.425
Type of disease	Eczema	10 (23.26)	12 (27.91)	10 (22.73)	1.389	0.572
	Vitiligo	13 (30.23)	10 (23.26)	11 (25.00)		
	Folliculitis	10 (23.26)	11 (25.58)	13 (29.55)		
	Herpes	7 (16.28)	8 (18.60)	7 (16.28)		
	Other	3 (6.98)	2 (4.65)	3 (6.82)		

3, 5, 7 and 10 days after surgery were measured. The wound tissues at various time points were reserved for homogenization, followed by centrifugation at 3000 rpm for 20 min. After retaining the supernatant, ELISA method was performed to measure FGF and EGF levels. Substance P concentration: 3 ml of venous blood was drawn in the early morning in the fasting state and centrifuged at 2000 rpm for 10 min, and supernatant was collected. Enzyme-linked immunosorbent assay (ELISA) purchased from Shanghai Yuanye Biotechnology Co., Ltd. [9] was used to determine the SP level.

Wound healing rate: the wound healing rate of the three groups was compared at 10, 20, and 30 days after surgery, respectively. Wound healing criteria [10]: no pain or any other symptoms. The scabs falling off revealed new skin underneath.

Appearance satisfaction [11]: The three groups of patients were evaluated for their satisfaction towards the appearance of the wound at 30 days after surgery, mainly for the quality of wound healing, the appearance, and the patient's feelings. A 0-10 scale was adopted, with 10 points indicating complete satisfaction, 7-9 points indicating basic satisfaction, and 6 points or less indicating dissatisfaction. Appearance satisfaction rate = complete satisfaction rate + basic satisfaction rate.

Statistical analysis

Statistical analysis was performed using SPSS 23.0. Count data were expressed as [n (%)] and compared by X² test. Measurement data were

expressed as ($\bar{x} \pm s$) and compared by *t* test. Multi-point comparisons were analyzed using ANVOA with post hoc F-test. Graphs were drawn using Graphpad Prism 8. *P*<0.05 indicated significant difference.

Results

Baseline data

There was no significant difference in terms of male and female proportion, mean age, mean disease duration, mean weight, mean body mass index (BMI) among groups A, B, and C (*P*>0.05) (**Table 1**).

Pain level of the wound

Pain level was decreased from the 3rd day after surgery to the 10th day after surgery in the three groups, and there was significant difference between adjacent time points (*P*<0.05) (**Figure 1**).

Syndrome scores

There was significant difference in the symptom scores at 1, 5, 10, 15, 20, 25, and 30 days after surgery among groups A, B, and C (*P*<0.05) (**Figure 2**).

FGF, EGF levels

FGF and EGF levels were increased from the 3rd day to the 10th day after completion of treatment in the three groups, and there was a significant difference between adjacent time points (*P*<0.05) (**Figures 1, 3-5**).

Comparison of changes in wound healing parameters

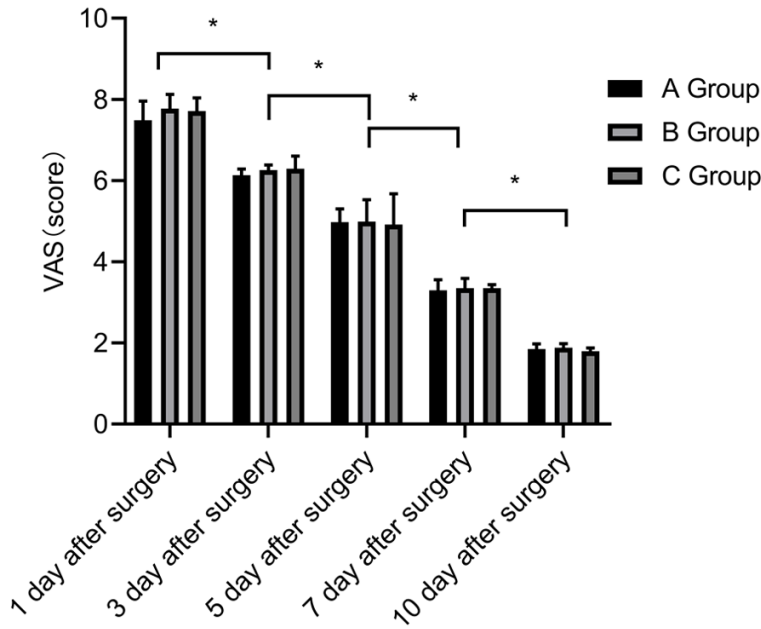


Figure 1. Pain level. VAS scores were gradually decreased in each of the three groups at 1, 3, 5, 7, and 10 days after surgery, with significant differences between the groups at different time points ($P<0.05$), $*P<0.05$.

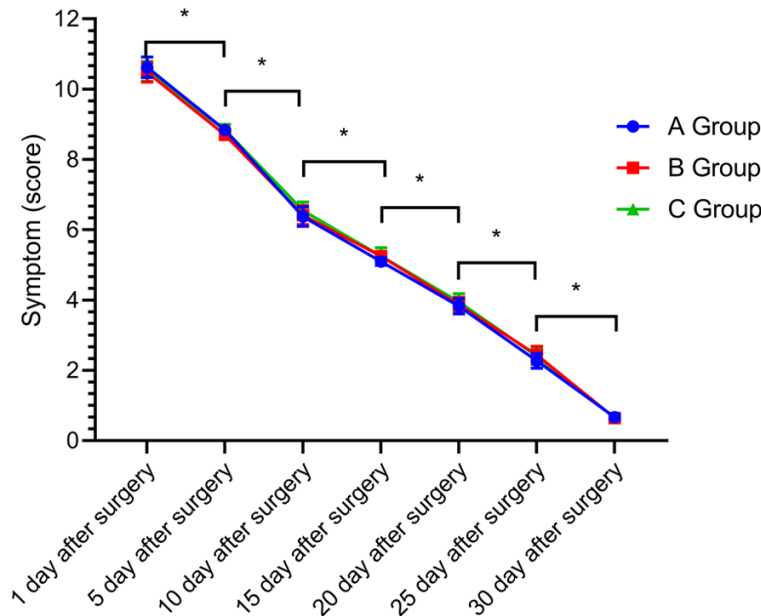


Figure 2. Symptomatic points. Symptomatic points were gradually decreased in each group at 1, 3, 5, 7, and 10 days after surgery, with significant differences between the three groups at different time points ($P<0.05$), $*P<0.05$.

Wound healing rate

The three groups showed the highest wound healing rate at 30 days after surgery ($P<0.05$) (Table 2).

Satisfaction towards appearance

There was no significant difference in overall satisfaction rate with the appearance of the wound at 30 days after surgery among groups A, B, and C ($P>0.05$) (Table 3).

Discussion

Postoperative wound care mainly includes wound protection and prevention of infection. Zihua Shaoshang Gao applied in this study could form an oily protective film on the surface of the wound to ensure that the wound remained moisturized and did not dry out [12]. The main components of comfrey contain a variety of naphthoquinone derivatives, such as isobutyl-shikonin, alkanin, and acetylshikonin, which can effectively inhibit fungi, *Pseudomonas aeruginosa*, and Gram-positive bacteria. Moreover, *Rehmannia glutinosa* contains β -glutamine, which can decrease capillary permeability and reduce bleeding and exudate. Borneol and pepper have been shown to inhibit the activity of bacteria and fungi, which can effectively protect wounds and control wound infections [13, 14]. It has been found that Zihua Shaoshang Gao can transform into an oil layer by mixing with tissue metabolites and exudates, causing the wound tissue to lose its lipophilic ability and detach them from the wound surface, thereby exerting a debridement activity [15].

The Angelica Shengji Yuhong Gao can resolve stasis and pain, stop bleeding and invigorate blood. Sesame oil and white wax can help moisten the skin and build muscle mass, which can act as an excipient. Mercurous

Comparison of changes in wound healing parameters

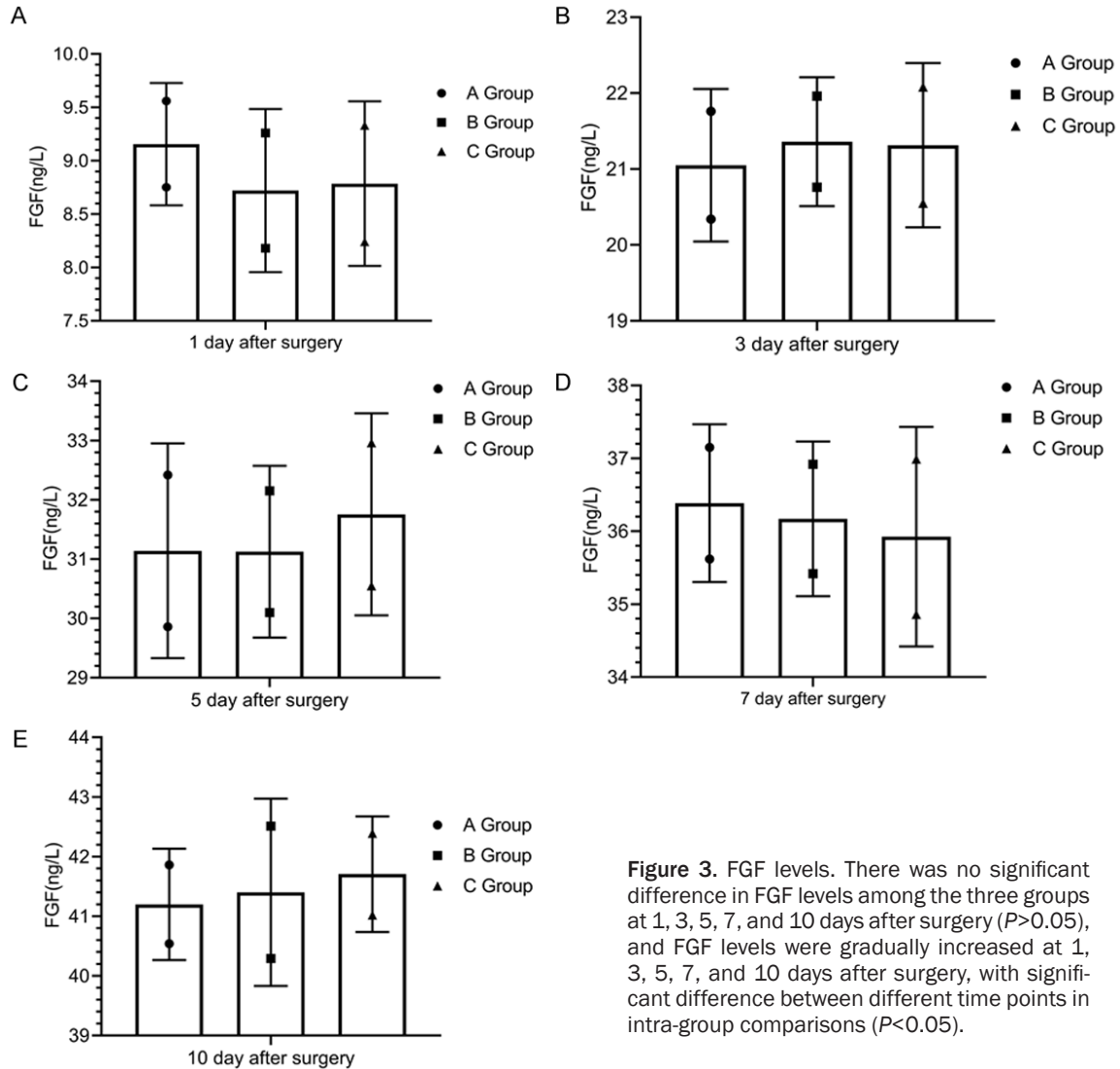


Figure 3. FGF levels. There was no significant difference in FGF levels among the three groups at 1, 3, 5, 7, and 10 days after surgery ($P>0.05$), and FGF levels were gradually increased at 1, 3, 5, 7, and 10 days after surgery, with significant difference between different time points in intra-group comparisons ($P<0.05$).

Chloride is capable of removing toxic and eliminating putrid, reducing dampness and astringency. Comfrey helps remove dampness and build muscle, cool blood and invigorate blood. *Angelica dahurica* helps reduce swelling, dry dampness and dispel wind; Draconis Sanguis could invigorate blood and heal wounds, resolve pain and stasis, build muscle and stop bleeding, while licorice can purging fire for removing toxin, and also play a harmonizing role for other herbs [16, 17]. *Scutellaria baicalensis* in Shirun Shaoshang Gao has a broad antibacterial spectrum. It can inhibit *Shigella*, *Streptococcus*, *Pseudomonas aeruginosa*, and *Staphylococcus* well, showing obvious detoxification, damp-drying and heat-clearing effects. Phellodendron Bark and Rhizoma Coptidis are proven to be effective against sputum bacteria, Hemolytic streptococcus, *Staphy-*

lococcus aureus, etc., and *Phellodendron* Bark could inhibit the activity of fungi. Both herbs contain berberine, which can enhance phagocytosis of white blood cells and inhibit *Staphylococcus aureus* effectively [18, 19]. The wounds in the three groups were covered with a dressing or gauze over the ointments. Importantly, the dressing was a transparent type, soft and comfortable. Caregivers can directly observe the wound from the outside, which is convenient for dealing with abnormalities. Moreover, the combination of dressing and the ointment can further form a protective film to isolate the wound from the external factors and effectively prevent infection [20].

In this study, there was no significant difference among groups A, B and C in VAS score, FGF, EGF, and SP levels at 1, 3, 5, 7 and 10 days

Comparison of changes in wound healing parameters

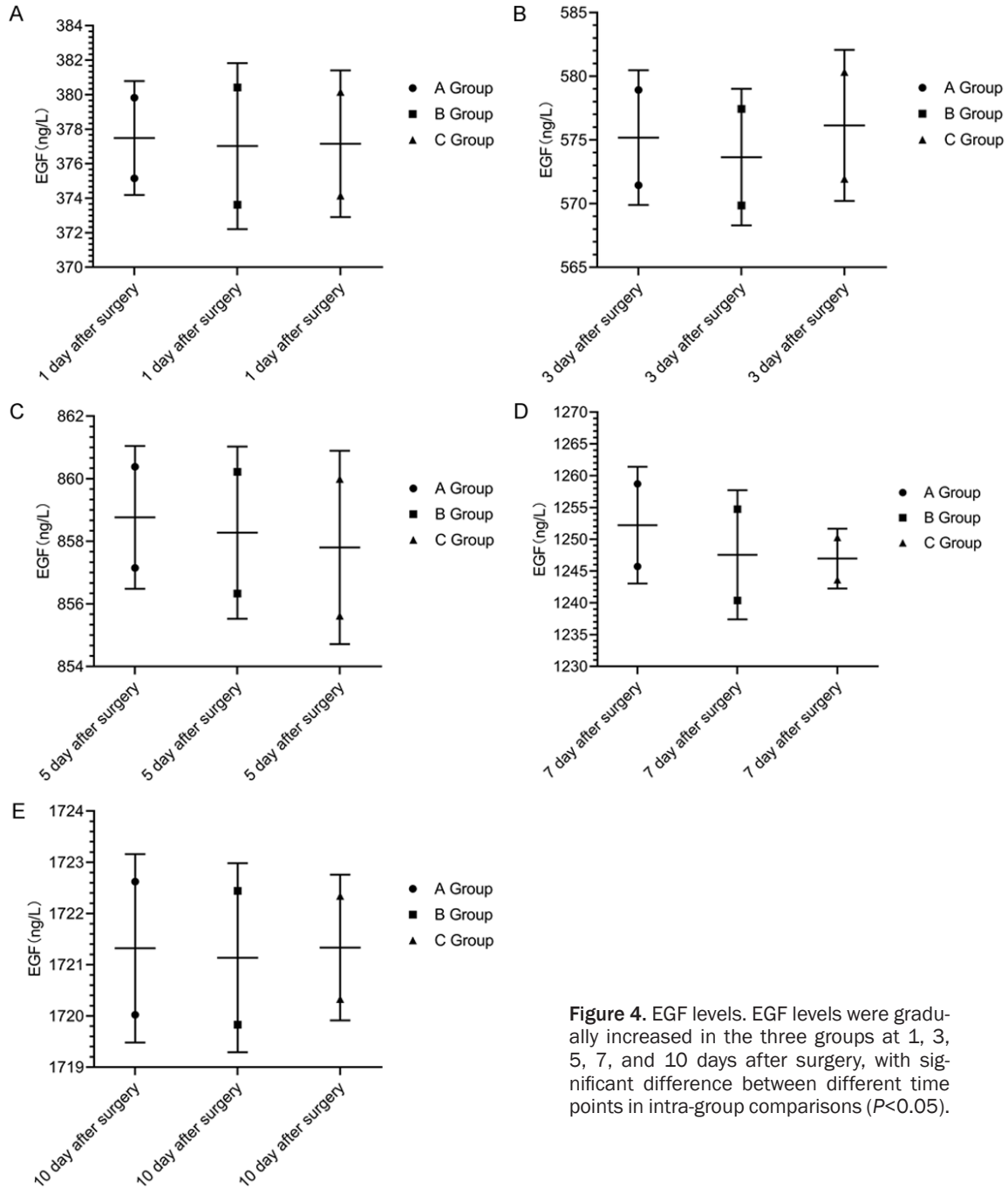


Figure 4. EGF levels. EGF levels were gradually increased in the three groups at 1, 3, 5, 7, and 10 days after surgery, with significant difference between different time points in intra-group comparisons ($P < 0.05$).

after surgery ($P > 0.05$), and there was no significant difference between groups at 1, 5, 10, 15, 20, 25 and 30 days after surgery ($P < 0.05$), suggesting that all the three skin care products can improve symptoms and control the pain level, and the efficacy becomes more pronounced over time. A previous study also showed that the VAS scores of Shengji Yuhong Gao for wound dressing change at 3, 7 and 10 days

after treatment were all lower than those before treatment, and were lower than those of the Western ointment group alone ($P < 0.05$) [21], which confirmed the pain control effect of the Chinese ointment as that in this study. Substance P is a kind of neuropeptides with high activity and is widely present in the nervous system and peripheral tissue airways. A variety of cells responsible for wound repairing

Comparison of changes in wound healing parameters

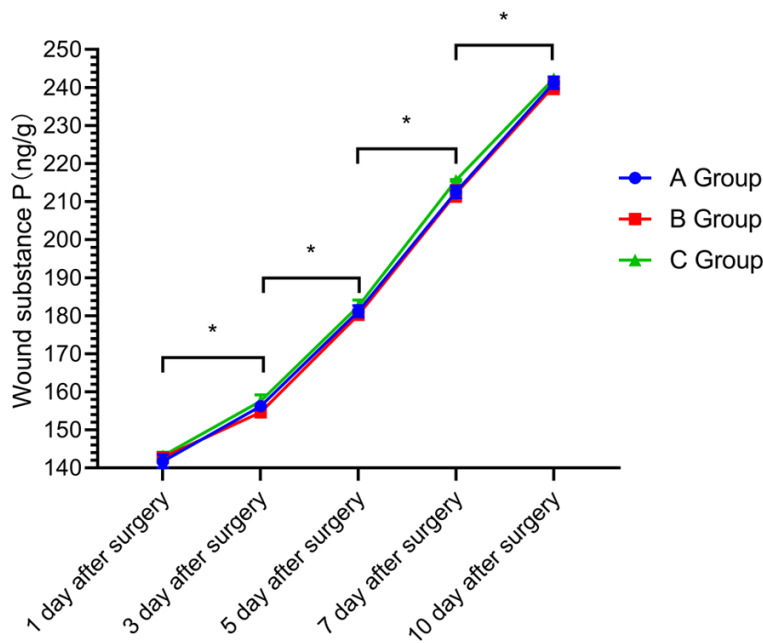


Figure 5. SP substance. Comparison of SP levels among three groups at different time points at 1, 3, 5, 7, and 10 days after surgery, with significant differences ($P < 0.05$), * indicates comparisons between different time points. $P < 0.05$.

Table 2. Comparison of wound healing rates among the three groups at different time point after surgery [n (%)]

Groups	Number of cases	10 days after surgery	20 days after surgery	30 days after surgery
Group A	43	11 (25.58)	28 (65.12)	41 (95.35)
Group B	43	9 (20.93)	29 (67.44)	43 (100.00)
Group C	44	11 (25.00)	26 (59.09)	43 (97.73)
χ^2		0.782	0.283	0.516
P		0.155	0.294	0.417

Table 3. Comparison of satisfaction with the appearance of the wound at 30 days after surgery in the three groups [n (%)]

Groups	Number of cases	Totally satisfied	Generally satisfied	Unsatisfied	Overall satisfaction
Group A	43	28 (65.12)	15 (34.88)	2 (4.65)	41 (95.35)
Group B	43	30 (69.77)	13 (30.23)	1 (2.33)	42 (97.67)
Group C	44	30 (68.18)	14 (31.82)	1 (2.27)	43 (97.73)
χ^2					1.529
P					0.635

can synthesize SP, which provides a good basis for wound healing [22]. In this study, SP levels of the three groups gradually increased over time, indicating that these Chinese creams could up-regulate the expression of SP. It was

found that patients still experience persistent pain, which directly affects the patient's emotional state, and may even cause adverse emotions, leading to poor compliance and ultimately delaying wound healing [23]. Therefore, postoperative pain management is the key factor. In this study, there was little difference in the wound healing rate among the groups A, B, and C at 10, 20, and 30 days after surgery ($P > 0.05$). However, the longer time indicated the higher wound healing rate, indicating that all these products could promote postoperative wound healing in a time-dependent manner, approaching 100% healing in about one month. In a previous study, the application of Shirun Shaoshang Gao in wound treatment after trauma surgery showed that the healing rate reached 96% after 1 month, which was consistent with this study [24]. Patients in groups A, B, and C were 95.35%, 97.67%, and 97.73% satisfied with their appearance at 30 days after surgery, with little difference among the three groups ($P > 0.05$), suggesting that all the three ointments exhibited high patient satisfaction, which was related to the fact that the three ointments could ensure a high wound healing rate. Studies have also confirmed that patient satisfaction with the appearance of wound is positively correlated with the quality of wound healing, thus rapid wound

healing is an important basis for obtaining high patient satisfaction [25].

Although similar studies have been published in the past, most of them used some kind of

Comparison of changes in wound healing parameters

ointment alone or compared with western medicine. In the same study, it is rare to compare the application efficacy of Zihua Shaoshang Ruangao, Shengji Yuhong Gao and Shirun Shaoshang Gao simultaneously. This study mainly compared the application effect of these three nursing ointments, which is innovative to some extent.

In summary, these care ointments have similar effects, with rapid wound healing and high patient satisfaction towards appearance. However, no control group was established in this study to determine whether these Chinese ointments were superior to Western ointments or other wound dressings, which should be further explored in future studies.

Disclosure of conflict of interest

None.

Address correspondence to: Ming Liu, Department of Oral and Maxillofacial-Head Neck Oncology, Shanghai Ninth People's Hospital, College of Stomatology, Shanghai Jiao Tong University School of Medicine, No. 639 Zhizaoju Road, Huangpu District, Shanghai 200011, China. Tel: +86-021-23271699-5205; E-mail: mingliu_jy@163.com

References

- [1] Brassolatti P, de Andrade ALM, Bossini PS, Otterço AN and Parizotto NA. Evaluation of the low-level laser therapy application parameters for skin burn treatment in experimental model: a systematic review. *Lasers Med Sci* 2018; 33: 1159-1169.
- [2] Liu BY, Liu BY, Li LF, He YF and Wang YR. The influence of zi-hua burn cream on the survival of random skin flaps in rats. *Zhonghua Zheng Xing Wai Ke Za Zhi* 2013; 29: 370-375.
- [3] Gao X, Cen Y and Song Y. Effect of ecdysterone on survival of random-pattern skin flap in rats. *Zhongguo Xiu Fu Chong Jian Wai Ke Za Zhi* 2009; 23: 1187-1190.
- [4] Sun GF, Zhang XF, Li HC, Pan LY, Chen YF, Xu K, FEng DX. Effect and mechanism study of Shengjiyuhong cream on transdifferentiation and collagen production of normal human dermal fibroblasts. *Zhonghua Zheng Xing Wai Ke Za Zhi* 2016; 32: 365-372.
- [5] Liu JZ and Li M. Effect of Shengji Yuhong plaster on the wound healing after anal fistula surgery. *J Hainan Med Univ* 2016; 000: 76-78.
- [6] Geara FB, Eid T, Zouain N, Thebian R, Andraos T, Chehab C, Ramia P, Youssef B and Zeidan YH. Randomized, prospective, open-label phase iii trial comparing mebo ointment with bifafine cream for the management of acute dermatitis during radiotherapy for breast cancer. *Am J Clin Oncol* 2018; 41: 1257-1262.
- [7] Lee Y, Kim S, Yang B, Lim C, Kim JH, Kim H and Cho S. Anti-inflammatory effects of brasicca oleracea var. capitata L. (Cabbage) methanol extract in mice with contact dermatitis. *Pharmacogn Mag* 2018; 14: 174-179.
- [8] Facco E, Stellini E, Bacci C, Manani G, Pavan C, Cavallin F and Zanette G. Validation of visual analogue scale for anxiety (VAS-A) in preanesthesia evaluation. *Minerva Anestesiol* 2013; 79: 1389-1395.
- [9] Gan SD and Patel KR. Enzyme immunoassay and enzyme-linked immunosorbent assay. *J Invest Dermatol* 2013; 133: e12.
- [10] Zomer HD and Trentin AG. Skin wound healing in humans and mice: challenges in translational research. *J Dermatol Sci* 2018; 90: 3-12.
- [11] Vaidya TS, Mori S, Khoshab N, Dusza SW, Bander T, Matros E, Rossi AM, Nehal KS and Lee EH. Patient-reported aesthetic satisfaction following facial skin cancer surgery using the FACE-Q skin cancer module. *Plast Reconstr Surg Glob Open* 2019; 7: e2423.
- [12] Wilson T. Economic and social impacts of tourism in Mexico. *Lat Am Perspect* 2008; 35: 37.
- [13] Mou JJ. Drug treatment of chemotherapy-induced phlebitis through its pathogenesis. *World Clin Drugs* 2010; 9: 16.
- [14] Yao Z, Wenhui L, Yingying S and Ya Y. Optimization of matrix composition for astragalus polysaccharides skincare product. *J Dali Univ* 2015; 8: 5.
- [15] Zaharah SS, Singh Z, Symons G and Reid J. Mode of action of abscisic acid in triggering ethylene biosynthesis and softening during ripening in mango fruit. *Postharvest Biol Technol* 2013; 75: 37-44.
- [16] Zhang Y. Analysis of combined therapy and treatment effect of localized ultraviolet irradiation and Shengji Yuhong cream on diabetic foot. *J Clin Nurs Res* 2019; 3: 2.
- [17] Wang JT, Zhang XQ and Yao C. Estimation of granulation growth by scores system on the treatment of 257 cases of chronic lower leg ulcer patients with traditional Chinese medicine of Shengji Yuhong Gao: a multicenter, double-blinded RCT. *Guide China Med* 2012; 34: 1.
- [18] Nassar MA, Ali AM, El Din H and Omar M. Comparative plasma phenylalanine and glutamate profiles in scalded rats treated with mebo or copper (I) nicotinate complex. *Ann Burns Fire Disasters* 2018; 31: 329-334.
- [19] El-Hadidy MR, El-Hadidy AR, Bhaa A, Asker SA and Mazroa SA. Role of epidermal stem cells in repair of partial-thickness burn injury after us-

Comparison of changes in wound healing parameters

- ing Moist Exposed Burn Ointment (MEBO®)) histological and immunohistochemical study. *Tissue Cell* 2014; 46: 144-151.
- [20] Rando T, Kang AC, Guerin M, Boylan J and Dyer A. Simplifying wound dressing selection for residential aged care. *J Wound Care* 2018; 27: 504-511.
- [21] Suvas S. Role of substance P neuropeptide in inflammation, wound healing, and tissue homeostasis. *J Immunol* 2017; 199: 1543-1552.
- [22] Leal EC, Carvalho E, Tellechea A, Kafanas A, Tecilazich F, Kearney C, Kuchibhotla S, Auster ME, Kokkotou E, Mooney DJ, LoGerfo FW, Pradhan-Nabzdyk L and Veves A. Substance P promotes wound healing in diabetes by modulating inflammation and macrophage phenotype. *Am J Pathol* 2015; 185: 1638-1648.
- [23] Matsuzaki K and Upton D. Wound treatment and pain management: a stressful time. *Int Wound J* 2013; 10: 638-644.
- [24] Ho TJ, Jiang SJ, Lin GH, Li TS, Yiin LM, Yang JS, Hsieh MC, Wu CC, Lin JG and Chen HP. The in vitro and in vivo wound healing properties of the Chinese herbal medicine "Jinchuang Ointment". *Evid Based Complement Alternat Med* 2016; 2016: 1654056.
- [25] Drost BH, van de Langenberg R, Manusama OR, Janssens AS, Sikorska K, Zuur CL, Klop WM and Lohuis PJ. Dermatography (Medical Tattooing) for scars and skin grafts in head and neck patients to improve appearance and quality of life. *JAMA Facial Plast Surg* 2017; 19: 16-22.