

## Original Article

# Diagnostic value of multi-slice spiral CT scan in lung compression ratio of patients with pulmonary contusion complicated by pneumothorax or hydropneumothorax

Jie Gou<sup>1</sup>, Zhengguo Jiang<sup>2</sup>, Peng Wang<sup>2</sup>, Li'na Wang<sup>1</sup>, Weijuan Chen<sup>1</sup>, Xiaodong Fang<sup>1</sup>

Departments of <sup>1</sup>Imaging, <sup>2</sup>Medical Service, 521 Hospital of Norinco Group, Xi'an, Shaanxi Province, China

Received November 25, 2020; Accepted December 18, 2020; Epub April 15, 2021; Published April 30, 2021

**Abstract:** Objective: This study was designed to explore the diagnostic value of multi-slice spiral CT (MSCT) scanning in lung compression ratio of patients with pulmonary contusion complicated by pneumothorax or hydropneumothorax. Methods: Seventy-eight patients with pulmonary contusions complicated by pneumothorax or hydropneumothorax treated in the Department of Emergency Surgery of our hospital were examined by CT and X-ray, and the diagnostic value of these two methods was observed. The correlation of lung compression ratio measured by multiplanar reconstruction (MPR) and volume rendering (VR) with W/D ratio was studied, and the formula between VR-measured lung compression ratio and W/D ratio was constructed using a one-variable linear regression equation. Results: The diagnostic rate of pulmonary contusions complicated by pneumothorax or hydropneumothorax measured by CT was higher than that by X-ray ( $P < 0.05$ ). Among the patients with pulmonary contusion diagnosed by CT, 45 were localized and 33 were extensive, and there were statistically significant differences in the incidence of comorbid rib fractures ( $P < 0.05$ ). The correlation of lung compression ratio measured by VR with W/D ratio measured by CT was analyzed, and the regression equation of the two was obtained by one-variable linear regression equation analysis: lung compression ratio =  $1.159 \times \text{W/D} - 1.034$ . VR-measured lung compression ratio measured was positively correlated with W/D ratio ( $r = 0.936$ ,  $P < 0.001$ ). Conclusion: CT is superior to X-ray in the diagnosis of pulmonary contusions complicated by pneumothorax or hydropneumothorax. The calculation of lung compression ratio using the formula of lung compression ratio =  $1.159 \times \text{W/D} - 1.034$  has certain clinical value and can improve clinical work efficiency.

**Keywords:** Multi-slice spiral CT, pulmonary contusion, pneumothorax or hydropneumothorax, lung compression ratio, diagnostic value

## Introduction

Pulmonary contusion refers to the effect of violence on the chest wall during external trauma, which reduces the lung volume and significantly increases the pressure inside the lung, resulting in pulmonary parenchymal congestion and edema; while following the removal of external forces, the chest springs back again to cause secondary injury to the injured lung [1]. Previous studies have shown that progressive exacerbation within 72 hours following pulmonary contusion can lead to death, with a mortality rate of 10-20% [2]. However, for those complicated by pneumonia, acute respiratory distress syndrome or acute lung injury, the mortality rate can be further increased [3]. Clinical stud-

ies have found that in the early stages of pulmonary contusions, the occurrence of pneumothorax or hydropneumothorax compresses the lungs and causes atelectasis, which in severe cases, leads to decreased lung function and can be fatal [4]. Therefore, early assessment of the condition of patients with pulmonary contusions, such as the extent of pneumothorax or hydropneumothorax, complicated fractures and corresponding treatment, is of positive significance to improve the prognosis of patients.

The treatment schemes vary, depending on the range of pneumothorax or hydropneumothorax and the ratio of lung compression [5, 6]. At present, plain chest film and chest CT scans

are widely used for the diagnosis of pneumothorax and lung compression. Visual methods including the three-wire method, average pleural spacing and optical index method, are widely used in the measurement of lung compression ratios. Although visual methods are simple to calculate, the research on lung compression ratios is relatively sparse. On the contrary, accurate measurement methods, such as multiplanar reconstruction (MPR) and volume rendering (VR) technique, are applicable to the early diagnosis and treatment of lung compression ratio despite the complexity of measurement data [7, 8]. With the advent of CT technique, multi-slice spiral CT (MSCT) has become popular in China, with high accuracy for pulmonary contusion, which makes it the gold standard for diagnosis of pneumothorax and hydropneumothorax [9]. However, at present, the use of MSCT plane image related data for the measurement of lung compression ratio is scanty and inconclusive.

In view of this, this study determines the correlation between the lung compression ratio and the ratio between the maximum width (W value) of the pneumothorax and the transdiaphragmatic thoracic maximum anteroposterior diameter (D value) on the cross section of MSCT, which provides a new measurement and evaluation method for clinical determination of lung compression ratio, and is beneficial to the early determination of lung compression ratio and the formulation of corresponding treatment schemes.

### Materials and methods

#### *Clinical data*

This study was approved by the Medical Ethics Committee of 521 Hospital of Norinco Group. From July 2018 to June 2019, 78 consecutive patients aged 18-70 years with pulmonary contusion complicated by pneumothorax or hydropneumothorax treated in the Department of Emergency Surgery of 521 Hospital of Norinco Group were selected. The patient or family members signed the informed consent form.

#### *Inclusion criteria*

The included patients (1) met the diagnostic criteria of pulmonary contusion complicated by pneumothorax or hydropneumothorax [10]; (2) aged  $\geq 18$  years; (3) were all examined by X-ray

film and MSCT before receiving treatment; (4) were diagnosed with pulmonary contusion complicated by pneumothorax or hydropneumothorax for the first time; (5) had pneumothorax or hydropneumothorax occurring unilaterally in the lungs; (6) had no other basic pulmonary underlying diseases such as pulmonary infection or chronic obstructive pulmonary disease.

#### *Exclusion criteria*

Patients excluded were those with (1) obvious pleural adhesion; (2) emphysema or lung bullae  $>5$  mm; (3) relatively regular pneumothorax morphology.

#### *Methods*

All patients underwent X-ray film and MSCT scan before treatment. The GE ADW 4.6 post-processing workstation used MPR and VR technique to reconstruct the lung volume, calculate the chest cavity volume and outline the compressed lung edge. Removing other redundant tissues, the compressed lung volume was worked out as follows: lung compression ratio =  $(1 - \text{lung compression volume} / \text{chest volume}) \times 100\%$ . The maximum width (W) of pneumothorax and the maximum anteroposterior diameter (D) of the transdiaphragmatic thorax were measured by the MSCT plane image.

#### *Outcome measures*

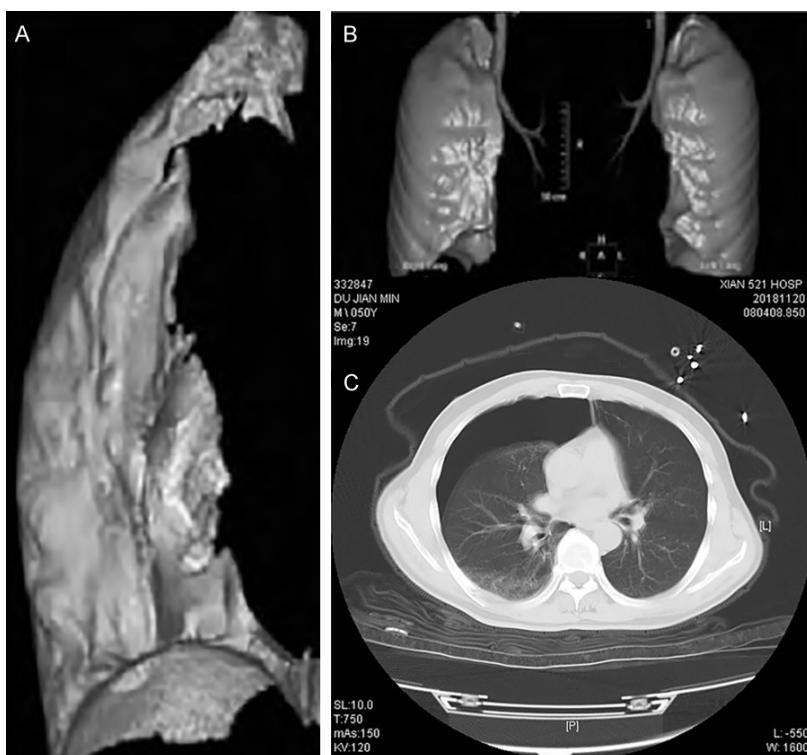
*Primary outcome measures:* The correlation between the lung compression ratio measured by VR and the W/D ratio was studied, and the formula between the two was constructed by the one-variable linear regression equation. VR was carried out in CT post-processing software (ADW 4.5). First, the thoracic inner edge curve was sketched, and the hilar area was bounded by the opening of the secondary branch of the bronchus. The minimum intensity projection (Min P) was used to reorganize and measure the original lung volume V1 of the affected side. Then the pneumothorax air shadow outside the compressed lung tissue was removed, and the compressed lung tissue volume V2 was reorganized and measured, so as to calculate the pneumothorax air volume (V1-V2) and obtain the lung compression ratio  $((V1-V2)/V1)\%$ . Thereafter, the maximum width (A value) of axial pneumothorax and the maximum anteroposterior diameter (B value) of

**Table 1.** Comparison of diagnosis of pulmonary contusion and related complications between the two groups (n)

Item	X-ray group (n=78)	CT group (n=78)	$\chi^2$	P
Pulmonary contusion	65	78	14.182	<0.001
Pneumothorax or hydropneumothorax	73	78	5.116	0.023
Rib fractures	45	47	2.043	0.153

**Table 2.** Rib fractures in patients with different types of pulmonary contusion complicated by pneumothorax or hydropneumothorax (n, %)

Item	No fracture	Single shot	Multiple shots	$\chi^2$	P
Localized (n=45)	17 (37.78)	13 (28.89)	15 (33.33)	6.402	0.041
Extensive (n=33)	16 (48.48)	2 (6.07)	15 (45.45)		

**Figure 1.** Display of pneumothorax by CT post-processing multiplanar reconstruction and VR. A and B: Multiplanar reconstruction and VR technique respectively; C: The CT plane image. VR: volume rendering.

transdiaphragmatic thorax were measured at different layers in the CT.

**Secondary outcome measures:** (1) X-ray and MSCT were compared regarding their diagnosis of pulmonary contusion. (2) X-ray and MSCT were compared in the diagnosis of complications of pulmonary contusion complicated by pneumothorax/hydropneumothorax and rib fractures.

### Statistical methods

SPSS 22.0 was used for statistical analyses. Continuous variables were expressed as mean  $\pm$  standard deviation ( $\bar{x} \pm sd$ ), and normally distributed data were tested by Shapiro-Wilk test. t-test was used for data that were consistent with a normal distribution and homogeneity of variance, and rank sum test was applied otherwise. The counting data were tested by Pearson Chi-square and represented by  $\chi^2$ . The difference was statistically significant when  $P < 0.05$ .

### Results

#### Comparison of the two methods in the diagnosis of pulmonary contusion and related complications

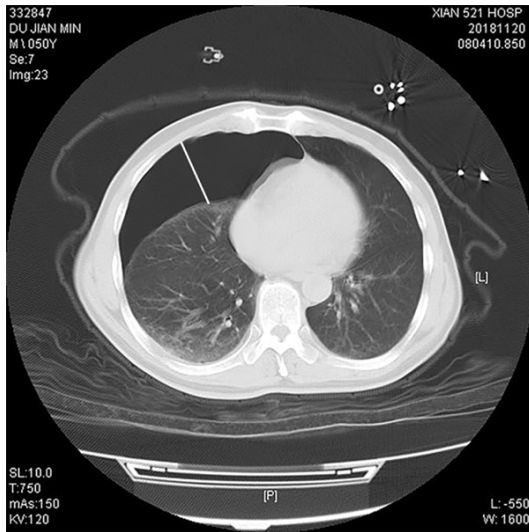
The diagnostic rate of CT in diagnosing pulmonary contusion complicated by pneumothorax or hydropneumothorax was higher than that of X-ray ( $P < 0.05$ ). See **Table 1**.

#### Comparison of rib fractures in patients with different types of pulmonary contusions complicated by pneumothorax or hydropneumothorax

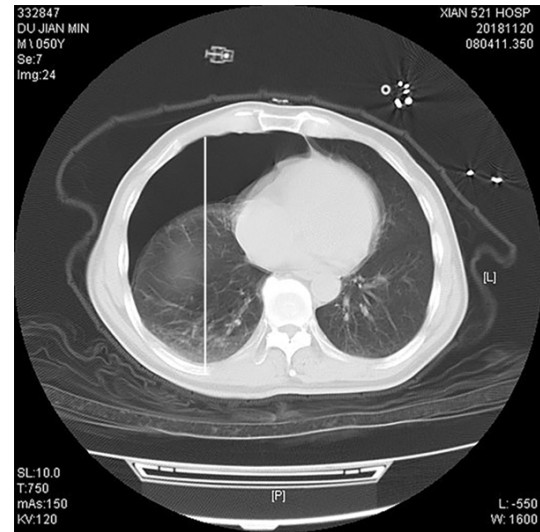
Among the patients with pulmonary contusion diagnosed by CT, 45 cases were localized and 33 were extensive, and there were statistically significant differences in the incidence of comorbid rib fractures ( $P < 0.05$ ). See **Table 2**.

#### CT images of lung compression ratio in patients with pulmonary contusion complicated by pneumothorax or hydropneumothorax

The lung volume was reconstructed by MPR and VR. The chest volume was calculated to



**Figure 2.** Maximum width (W value) of pneumothorax in cross-sectional CT image (white line).



**Figure 3.** Maximum anteroposterior diameter (D value) of the transdiaphragmatic thorax (white line) in CT image.

delineate the compressed lung edge, and the compressed lung volume was calculated by removing other redundant tissues (**Figure 1**). The maximum width (W) of the pneumothorax and the maximum anteroposterior diameter (D) of the transdiaphragmatic thorax were also found in CT images **Figures 2, 3**.

*Correlation analysis between lung compression ratio measured by VR technique and W/D ratio*

Through one-variable linear regression analysis, the regression equation was obtained as follows: lung compression ratio =  $1.159 \times W/D - 1.034$ . The lung compression ratio measured by VR technique was positively correlated with the W/D ratio ( $r=0.936$ ,  $P<0.001$ ). See **Table 3** and **Figure 4**.

## Discussion

Pulmonary contusion is the lung injury caused by external force, and its pathological changes are mainly manifested as lung parenchymal cell damage, pulmonary edema and hemorrhage, as well as death caused by acute respiratory distress syndrome (ARDS) in severe cases [11-13]. Pulmonary contusion complicated by pneumothorax or hydropneumothorax is a common clinical condition. Different degrees of pneumothorax or hydropneumothorax lead to different lung compression ratios, and different treatment schemes and prognosis [14].

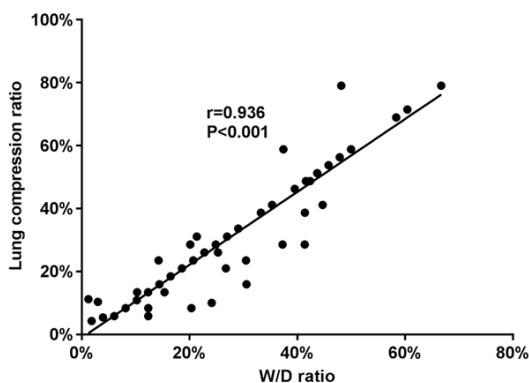
X-ray is a common clinical method for diagnosing lung diseases because of its simplicity and rapidness, but it is prone to miss and delay diagnosis due to its rough display image and interference of tissue overlapping [15]. This study also found that CT diagnosis of pulmonary contusion, pneumothorax, hydropneumothorax and rib fractures was all 100% higher than X-ray diagnosis, which was consistent with the above research results. Further research indicated that the condition of rib fractures was also different in different types of pulmonary contusions: the localized pulmonary contusion was mostly single fracture while the extensive type was mostly multiple fractures.

Pulmonary contusions complicated by different degrees of pneumothorax or hydropneumothorax lead to different clinical treatment methods and different prognosis. For patients with pulmonary contusions complicated by a small amount of pneumothorax or hydropneumothorax, symptomatic treatment and oxygen inhalation are sufficient, while for those with large amounts of fluid pneumothorax and hydropneumothorax, thoracic closed drainage is required [16, 17]. In clinic, conservative treatment schemes can be adopted for patients with lung compression ratio below 30%, while a closed thoracic drainage scheme is needed for those with  $\geq 30\%$ . Early accurate determination of lung compression ratio has become a conundrum in clinical research because the

**Table 3.** Correlation analysis between W/D ratio and lung compression ratio measured by VR technique ( $\bar{x} \pm sd$ )

Lung compression ratio measured by VR technique (%)	W/D ratio (%)	r	P
28.94±18.05	25.87±14.59	0.936	<0.001

Note: VR: volume rendering.

**Figure 4.** Correlation analysis between lung compression ratio measured by VR technique and W/D ratio. VR: volume rendering.

lungs are located inside the chest cavity and have irregular morphology. As early as 2001, a domestic project scanned 17 lung models layer by layer and mapped out the complete outline of the lungs at each corresponding level. Then, the computer layer area calculation function was used to calculate the area of the total number of layers, and then it was multiplied by a fixed height to obtain the lung volume. Therefore, it is considered that CT can be used to calculate the lung volume [18]. Further, research used CT to calculate the area of one side of lung cavity, outlined the area of gas contained in the chest, and took the ratio of the two as the lung compression ratio [19]. Whereas, with the popularization of MSCT, research shows that lung volume can be displayed and calculated using the VR technique [20, 21]. Although the above research methods are more accurate, their calculation amount is huge and inconsistent with the needs of clinical work. In view of this, we further explored the simple and reliable indicators suitable for clinical use, and selected all levels of MSCT for brushing. The maximum width (W) of axial pneumothorax or hydropneumothorax was selected to replace the compressed lung volume, and the transdiaphragmatic chest maximum anteroposterior diame-

ter (D) to replace the total volume of unilateral lung for the calculation of the ratio of the two, namely, W/D. Then, VR technique was used to accurately work out the lung compression ratio. The two variables obtained above were analyzed by linear regression to get the equation of lung compression ratio =  $1.159 * W/D - 1.034$ , which can be used as the calculation method of lung compression ratio.

Shortcomings and prospects: due to the small sample size and since the inclusion types were mainly patients with free pneumothorax or hydropneumothorax, the calculation error increased due to the occurrence of thoracic deformation and pleural adhesion caused by trauma, which is not conducive to clinical judgment. Therefore, it is still necessary to further expand the sample size and study the patients with pulmonary contusions complicated by other conditions of pneumothorax or hydropneumothorax.

To sum up, CT is superior to X-ray in the diagnosis of pulmonary contusion complicated by pneumothorax or hydropneumothorax. The calculation of pulmonary compression ratio using the formula of pulmonary compression ratio =  $1.159 * W/D - 1.034$  has certain clinical value and can improve clinical work efficiency.

#### Disclosure of conflict of interest

None.

**Address correspondence to:** Xiaodong Fang, Department of Imaging, 521 Hospital of Norinco Group, No. 12 Zhangba East Road, Yanta District, Xi'an 710065, Shaanxi Province, China. Tel: +86-029-88265163; E-mail: fangxiaodong128d@163.com

#### References

- [1] Rendeki S and Molnar TF. Pulmonary contusion. J Thorac Dis 2019; 11 Suppl 2: S141-S151.
- [2] Mahmood I, El-Menyar A, Younis B, Ahmed K, Nabir S, Ahmed MN, Al-Yahri O, Mahmood S, Consunji R and Al-Thani H. Clinical significance and prognostic implications of quantifying pulmonary contusion volume in patients with blunt chest trauma. Med Sci Monit 2017; 23: 3641-3648.

- [3] Daurat A, Millet I, Roustan JP, Maury C, Taourel P, Jaber S, Capdevila X and Charbit J. Thoracic trauma severity score on admission allows to determine the risk of delayed ARDS in trauma patients with pulmonary contusion. *Injury* 2016; 47: 147-153.
- [4] Dries DJ. ARDS: from syndrome to disease: prevention and genomics. *Air Med J* 2019; 38: 7-9.
- [5] Qiao GB and Chen G. Treatment of spontaneous pneumothorax: guangdong thoracic surgery industry consensus (2016 Edition). *Chin J Clin Thorac Cardiovasc Surg* 2017; 24: 6-15.
- [6] Cai WL, Lee JG, Fikry K, Yoshida H, Novelline R and de Moya M. MDCT quantification is the dominant parameter in decision-making regarding chest tube drainage for stable patients with traumatic pneumothorax. *Comput Med Imaging Graph* 2012; 36: 375-386.
- [7] Salazar AJ, Aguirre DA, Ocampo J, Camacho JC and Díaz XA. Evaluation of three pneumothorax size quantification methods on digitized chest X-ray films using medical-grade grayscale and consumer-grade color displays. *J Digit Imaging* 2014; 27: 280-286.
- [8] Montanari G, Orso D, Guglielmo N and Copetti R. Comparison of different methods of size classification of primary spontaneous pneumothorax. *Am J Emerg Med* 2018; 36: 327-328.
- [9] Pozgajin Z, Kristek D, Lovric I, Kondža G, Jelavić M, Kocur J and Danilović M. Pulmonary contusions after blunt chest trauma: clinical significance and evaluation of patient management. *Eur J Trauma Emerg Surg* 2018; 44: 773-777.
- [10] Huang X, Xiu H, Zhang S and Zhang G. The role of macrophages in the pathogenesis of ALI/ARDS. *Mediators Inflamm* 2018; 2018: 1264913.
- [11] Patel VJ, Roy SB, Mehta HJ, Joo M and Sadikot RT. Alternative and natural therapies for acute lung injury and acute respiratory distress syndrome. *Biomed Res Int* 2018; 2018: 2476824.
- [12] Hughes KT and Beasley MB. Pulmonary manifestations of acute lung injury; more than just diffuse alveolar damage. *Arch Pathol Lab Med* 2017; 141: 916-922.
- [13] Kolomaznik M, Nova Z and Čalkovska A. Pulmonary surfactant and bacterial lipopolysaccharide: the intertactum and its functional consequence. *Physiol Res* 2017; 66 Suppl 2: S147-S157.
- [14] Cohn SM and Dubose JJ. Pulmonary contusion: an update on recent advances in clinical management. *World J Surg* 2010; 34: 1959-1970.
- [15] Kelly AM, Weldon D, Tsang AY and Graham CA. Comparison between two methods for estimating pneumothorax size from chest X-rays. *Respir Med* 2006; 100: 1356-1359.
- [16] Park J, Pabon M, Choi AMK, Siempos II, Fredenburgh LE, Baron RM, Jeon K, Chung CR, Yang JH, Park CM and Suh GY. Plasma surfactant protein-D as a diagnostic biomarker for acute respiratory distress syndrome: validation in US and Korean cohorts. *BMC Pulm Med* 2017; 17: 204.
- [17] Nishiumi N, Nakagawa T, Masuda R, Iwasaki M, Inokuchi S and Inoue H. Endobronchial bleeding associated with blunt chest trauma treated by bronchial occlusion with a univent. *Ann Thorac Surg* 2008; 85: 245-250.
- [18] Xia WQ and Lu M. Study on the accuracy of CT evaluation of lung tissue compression volume (percentage) after pneumothorax. *J Pract Radiol* 2001; 17: 881-882.
- [19] Wang CL, Dong HB and Chen JQ. CT measurement and diagnosis of lung compression rate of pneumothorax. *Chin J Trauma* 2002; 18: 115-116.
- [20] Yang YJ, Shang M, Li YW, Luo XT, Li J, Ma SL and Li F. Use MSCT to estimate lung volume in normal people. *J Forensic Med* 2018; 34: 504-507.
- [21] Yang F, Hu HP, Xu XL, Zhu XN, Wei WX, Guo ZG, Liu Z, Pu ZY, Yang XQ, Li F and Zhao Y. Research on MDCT tissue segmentation technology to determine lung compression ratio in pneumothorax and liquid pneumothorax. *J Med Imaging* 2016; 26: 1602-1605.