

Original Article

Differential expressions of carcinoembryonic antigen and squamous cell carcinoma antigen in patients with advanced cervical cancer undergoing chemotherapy

Xuelian Bai*, Bo Liu*, Yun Wu, Chunyan Wu, Lifeng Zhao, Lijun Wang, Haixiang Yang

*Department of Oncology, Baotou Central Hospital, Baotou 014040, China. *co-first authors.*

Received February 28, 2021; Accepted May 11, 2021; Epub October 15, 2021; Published October 30, 2021

Abstract: Objective: Cervical cancer is a malignant tumor commonly found in women. This study was conducted to discuss the differential expression of carcinoembryonic antigen (CEA) and squamous cell carcinoma antigen (SCCA) in patients with advanced cervical cancer undergoing various chemotherapies and their effects on patient safety. Methods: A total of 65 patients admitted to our hospital with advanced cervical cancer were included as the study subjects and were divided into two groups based on the chemotherapy they received: control group (n = 31) and observation group (n = 34). After two cycles of systemic (IV) chemotherapy in the control group and intra-arterial infusion chemotherapy in the observation group, the two groups were compared for treatment efficacy. Results: After chemotherapy, the effective rate was 76.47% in the observation group and 48.39% in the control group ($P < 0.05$). The CEA and SCCA levels were reduced in the two groups, and the observation group had significantly lower levels than the control group ($P < 0.05$), and also in patients with CR and PR ($P < 0.05$). Conclusion: In patients with advanced cervical cancer, intra-arterial infusion chemotherapy can improve the efficacy and short-and long-term survival, and reduce the serum VEGF level, blood flow in the tumor, metastasis, and reoccurrence.

Keywords: Advanced cervical cancer, carcinoembryonic antigen, squamous cell carcinoma antigen, chemotherapy, toxic reactions

Introduction

Cervical cancer is a common malignant tumor in women. Annually, the newly reported cases of cervical cancer in China account for approximately 28.8% of all global cases. Most patients are young women, especially those aged < 35 years, and the incidence is on the rise [1]. In cervical cancer, the tumor cells infiltrate and invade the surrounding tissues. Therefore, patients with advanced cervical cancer may exhibit local or general symptoms correspondingly, including pains, frequent micturition, urgent urination, as well as swelling and pain in the lower extremities. For patients with advanced cervical cancer who are unsuitable for or unwilling to undergo surgical treatment, chemotherapy as classical treatment includes systematic (IV) chemotherapy and intra-arterial infusion chemotherapy, with most clinical applications using different routes of administration. Some

studies [2-4] have revealed that intra-arterial infusion chemotherapy is superior to systematic (IV) chemotherapy with respect to short-term treatment efficacy. The development and progress of the tumor is generally accompanied by abnormal expression of molecular tumor markers, while carcinoembryonic antigen (CEA) and squamous cell carcinoma antigen (SCCA) are the major indices for clinical diagnosis of a malignant tumor. CEAs are mostly found in the gastrointestinal epithelial cells, on the surface of some tumor cells in colon cancer and lung cancer. SCCAs are mainly present in squamous cell (SC) tissues in cervical cancer. Their release into the serum may result in abnormal expression of molecular tumor markers. In the present study, the efficacy and safety of different chemotherapies in patients with advanced cervical cancer and the resultant changes in the expression of serum CEA and SCCA were observed and reported.

Materials and methods

General materials

A total of 65 patients with advanced cervical cancer admitted to our hospital were included as the study subjects and were retrospectively analyzed. As per the inclusion criteria, patients who were diagnosed with cervical cancer classified as squamous cell carcinoma stage IIb-IIIb based on pathological biopsies and according to International Federation of Gynecology and Obstetrics were included on the basis of an expected survival of > 3 months and ECOG score of < 2. They had not previously received nor had any contraindications against chemotherapy. All included patients signed an informed consent form and agreed to cooperate with the follow-ups. As per the exclusion criteria, some patients were excluded as they were > 70 years old, had undergone surgical treatment, had hepatic and renal insufficiency, had other malignant tumors concurrently, or had a history of surgeries in the pelvis. The patients were divided into the control group (n = 31) and the observation group (n = 34) according to the chemotherapy they received. This study was approved by the Ethics Committee of the Baotou Central Hospital. All study participants provided written informed consent before participating in the study.

Methods

The control group received systematic (IV) chemotherapy, including intravenous drip of 1 mg leucovorin (Haizheng Huirui Pharmaceutical Co., Ltd., GYZZ No. H20043326, specification) at 1 mg/m², 10 mg cisplatin (Qilu Pharmaceutical Co., Ltd., GYZZ No. H37021358, specification) at 70 mg/m², and 15 IU bleomycin (Hanhui Pharmaceutical Co., Ltd., GYZZ No. H20055-883, specification) at 20 mg/m². The treatment consisted of two cycles at an interval of 1 week. The observation group received intra-arterial infusion chemotherapy, including intravenous drip of leucovorin 0.5 h before treatment, ultrasonography-guided uterine artery puncturing to insert the catheter into the uterine artery or the anterior trunk of the internal iliac artery, perfusion of cisplatin at 70 mg/m² and bleomycin at 20 mg/m² via microcatheter, and embolization with a gelatin sponge. The treatment consisted of two cycles at an interval of 4

weeks. After treatment, both groups were additionally treated with radiotherapy, wherein the anterior and posterior pelvic cavity were separately exposed at an intensity of 2 Gy/time for five times a week, with the total exposure dose of 40-45 Gy.

Evaluation criteria

(1) Efficacy: the two groups were evaluated after two cycles of chemotherapy, and the result was graded as complete response (CR) if the former sites had completely disappeared, partial response (PR) if the former sites had shrunk by ≥ 50% but failed to disappear while no new sites developed, no change (NC) if the former sites had shrunk < 50% or expanded < 25% while no new sites developed, progressive disease (PD) if new sites had developed or the former sites had expanded by ≥ 25%. Effective rate = (CR + PR)/n in group × 100%. (2) Serum CEA and SCCA levels: 5 mL of blood was drawn from the veins of the patients before and after two cycles of chemotherapy, centrifuged at 3000 rpm for 10 min, and tested for CEA and SCCA levels using the chemiluminescence method with the I2000 automatic chemiluminescence immune analyzer and supporting reagents from Abbott U.S. (3) Blood flow in the tumor: before chemotherapy and at 2 weeks after chemotherapy, the two groups were tested for uterine artery pulsatility index and flow index (FI) using TH-5200 full digital CDU diagnostic apparatus from Beijing Teknova Digital Technology Co., Ltd., and microvessel density (MVD) in the cervical cancer tissues with double staining technology in immunohistochemistry; the result was the mean value of five visual fields observed under 400× lens. (4) Vascular endothelial growth factor (VEGF) level: 5 mL of blood was drawn from the veins of the patients before chemotherapy and after two cycles of chemotherapy, centrifuged at 3000 rpm for 10 min, and tested for VEGF-A, VEGF-C, and VEGF-D levels with enzyme-linked immunosorbent assay (ELISA) using test kits from Becton-Dickinson, U.S. (5) Chemotherapy-related toxic reaction: evaluation was performed according to NCI-CTC developed by the National Cancer Institute, and toxic reactions graded between III and IV were recorded. (6) Patients were followed for 1-3 years to record their rates of survival, metastasis, and recurrence.

Table 1. Comparison of the general characteristics of the two groups ($\bar{x} \pm s$, n)

Group	n	Average age (year)	Tumor diameter (cm)	Clinical staging			Lymphatic metastasis	
				IIb	IIIa	IIIb	Yes	No
Observation group	34	56.47 ± 5.39	4.38 ± 0.25	12	17	5	12	22
Control group	31	57.16 ± 5.82	4.33 ± 0.21	12	16	3	13	18
χ^2/t	-	0.496	0.869	0.393			0.302	
P	-	0.621	0.388	0.822			0.583	

Table 2. Comparison of the clinical efficacy in the two groups [n (%)]

Group	n	CR	PR	NC	PD	Effective rate
Observation group	34	4 (11.76)	22 (64.71)	6 (17.65)	2 (5.88)	26 (76.47)
Control group	31	3 (9.68)	12 (38.71)	13 (41.93)	3 (9.68)	15 (48.39)
χ^2	-	-	-	-	-	5.491
P	-	-	-	-	-	0.019

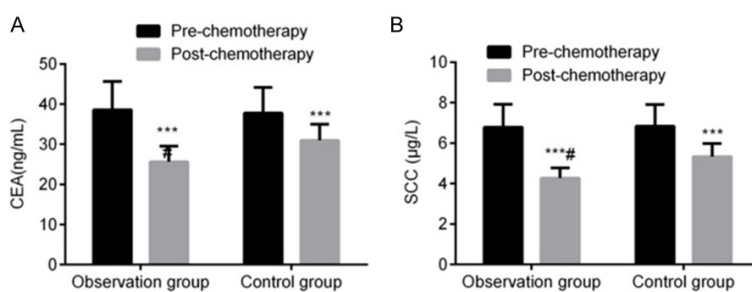


Figure 1. Comparison of the serum levels of CEA and SCCA between the two groups ($\bar{x} \pm s$). Note: *** $P < 0.001$ for the comparison with pretreatment conditions; # $P < 0.05$ for the comparison with the control group.

Significant improvement in the clinical efficacy using intra-arterial infusion chemotherapy

The effective rate was 76.47% in the observation group and 48.39% in the control group ($P < 0.05$), indicating that intra-arterial infusion chemotherapy could significantly improve the clinical effects compared with systematic (IV) chemotherapy (Table 2).

Statistical analysis

Statistical analyses were performed with SPSS 19.0. Statistical charts were produced with Graphpad Prism 8. In case of numerical data expressed as $\bar{x} \pm s$, comparison studies were performed using t test; in case of nominal data expressed as %, comparison studies were conducted with χ^2 test. For all statistical comparisons, significance was defined as $P < 0.05$.

Results

Clinical materials

The control group enrolled 31 patients with the mean age of (57.16 ± 5.82) years, while the observation group enrolled 34 patients with the mean age of (56.47 ± 5.39) years. Age, tumor diameter, clinical staging, and clinical data about the metastasis of lymphonodi were not significantly different ($P > 0.05$) between the two groups (Table 1).

Significant reduction in the serum levels of CEA and SCCA using intra-arterial infusion chemotherapy

The serum levels of CEA and SCCA of the two groups were comparable ($P > 0.05$) before chemotherapy. The levels in both the groups were reduced after treatment, and the serum levels of CEA and SCCA were significantly lower in the observation group than in the control group ($P < 0.05$), indicating that intra-arterial infusion chemotherapy could significantly reduce the serum CEA and SCCA levels in patients with cervical cancer (Figure 1).

Comparison among patients who exhibited different effects on the serum levels of CEA and SCCA before and after chemotherapy

The CEA and SCCA levels were reduced in CR and PR patients ($P < 0.05$), but were not significantly changed in NC patients ($P > 0.05$) and were increased in PD patients ($P < 0.05$), sug-

Table 3. Comparison of the CEA and SCCA levels of the patients with various treatments before and after chemotherapy ($\bar{x} \pm s$)

Indices		CR (n = 7)	PR (n = 34)	NC (n = 19)	PD (n = 5)
CEA (ng/mL)	Before chemotherapy	37.89 ± 6.82	38.15 ± 6.76	37.64 ± 7.14	37.96 ± 7.21
	After chemotherapy	13.60 ± 2.63	18.04 ± 3.09	38.22 ± 4.65	51.39 ± 5.94
T	-	8.792	7.158	0.180	-3.804
P	-	< 0.001	< 0.001	0.860	0.003
SCCA (μg/L)	Before chemotherapy	6.69 ± 1.12	6.78 ± 1.15	6.86 ± 1.09	6.92 ± 1.17
	After chemotherapy	2.72 ± 0.25	3.93 ± 0.23	6.47 ± 1.26	9.85 ± 1.35
T	-	9.153	25.402	0.619	4.339
P	-	< 0.001	< 0.001	0.547	0.001

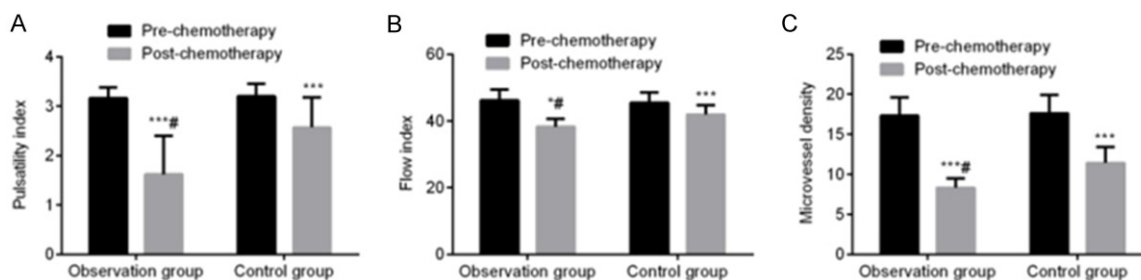


Figure 2. Comparison of the uterine artery hemodynamics and MVD between the two groups ($\bar{x} \pm s$). Note: * $P < 0.05$ and *** $P < 0.001$ for the comparison with pretreatment conditions; # $P < 0.05$ for the comparison with the control group.

gesting that serum levels of CEA and SCCA could reflect the tumor burden after chemotherapy (Table 3).

Significant improvement in the uterine artery hemodynamics and MVD after intra-arterial infusion chemotherapy

No significant difference was noted in the uterine artery PI, FI, and MVD before chemotherapy ($P > 0.05$) in the two groups. However, there was a reduction in these indices after treatment in both groups, and the uterine artery PI, FI, and MVD were significantly lower in the observation group than in the control group ($P < 0.05$), indicating that intra-arterial infusion chemotherapy could significantly improve the uterine artery hemodynamics and MVD (Figure 2).

Significant improvement in the serum level of VEGF after intra-arterial infusion chemotherapy

The two groups had no significant difference in the serum level of VEGF-A, VEGF-C, and VEGF-D before chemotherapy ($P > 0.05$). These indices

exhibited reduction in both groups after treatment, and the serum level of VEGF-A, VEGF-C, and VEGF-D were significantly lower in the observation group than in the control group ($P < 0.05$), suggesting that intra-arterial infusion chemotherapy could significantly improve serum levels of VEGF-A, VEGF-C and VEGF-D in patients (Figure 3).

Comparison of chemotherapy-related toxic reactions from grades III to IV and the 1-year and 3-year rates of survival, metastasis, and reoccurrence between the two groups

The two groups had no significant difference in the incidence of chemotherapy-related toxic reactions from grades III to IV ($P > 0.05$, Table 4). The observation group had significantly lower 1-year and 3-year rates of survival, metastasis, and reoccurrence than the control group ($P < 0.05$, Table 5).

Discussion

Cervical cancer is the second most common gynecological tumor and accounts for 73%-93% of all malignant tumors in the reproductive

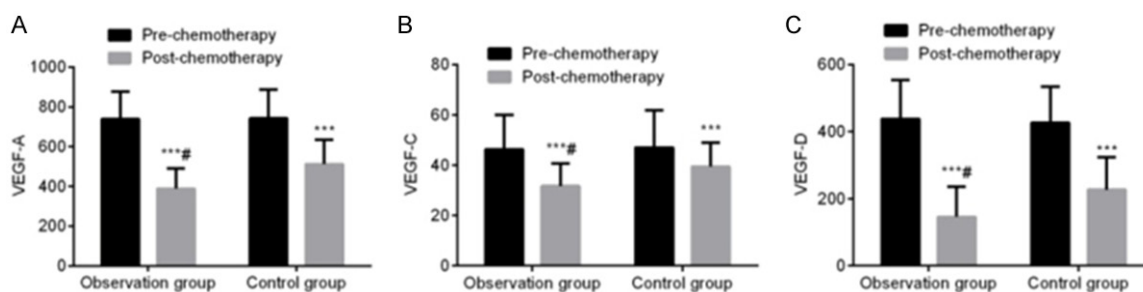


Figure 3. Comparison of the serum levels of VEGF between the two groups ($\bar{x} \pm s$, ng/L). Note: *** $P < 0.001$ for comparison with pretreatment conditions; # $P < 0.05$ for comparison with the control group.

Table 4. Comparison of the toxic reactions between grades III and IV in the two groups [n (%)]

Group	N	Leukopenia	Thrombocytopenia	Nausea/Vomiting	Diarrhea	Renal function damage	Cystitis	Dermal toxicity
Observation group	34	3 (8.82)	4 (11.76)	3 (8.82)	2 (5.88)	1 (2.94)	0 (0.00)	2 (5.88)
Control group	31	6 (19.35)	6 (19.35)	5 (16.13)	2 (6.45)	2 (6.45)	1 (3.23)	7 (22.58)
χ^2	-	0.754	0.253	0.268	0.178	0.007	0.000	2.520
P	-	0.220	0.397	0.371	0.924	0.501	1.000	0.052

Table 5. Comparison of the prognosis in the two groups [n (%)]

Group	n	Survival		Metastasis		Recurrence	
		1-year	3-year	1-year	3-year	1-year	3-year
Observation group	34	30 (88.23)	21 (61.76)	2 (5.88)	11 (32.35)	3 (8.82)	12 (35.29)
Control group	31	20 (64.52)	11 (35.48)	9 (29.03)	18 (58.06)	10 (32.26)	19 (61.29)
χ^2	-	5.139	4.481	6.181	4.338	5.566	4.393
P	-	0.024	0.034	0.013	0.037	0.018	0.036

system of women aged 40-60 years [5]. Although the tumor originates in a special organ with insidious causes that no obvious symptoms can be found in the early stage, most patients are diagnosed at an advanced stage wherein they complain of abnormal bleeding or vaginal discharge and miss the best chance for radical resection. As a result, they have to choose between more conservative treatments such as radiotherapy and chemotherapy. Molecular tumor markers are substances produced during the process of tumor development, progression, and metastasis and are closely related to the prognosis [6]. Studies [7-9] have proved that the expression of molecular tumor markers in patients with cervical cancer may be affected by various treatment methods such as surgery, radiotherapy and thermotherapy.

Cisplatin is a metal platinum complex that disrupts the DNA replication pathway of tumor cells and suppresses their reproduction and

growth to resist tumors, while leurocristine is a natural base extracted from catharanthus roseus of Apocynaceae with effects against tumors, and bleomycin a broad spectrum antitumor drug that disturbs the DNA of tumor cells by breaking the single strand and double strands, and blocks reproduction pathways [10]. In systemic (IV) chemotherapy, the patients are administered chemotherapy drugs via the veins where the drugs are transported to most of the organs and tissues via the circulating blood to fight against tumors. Intra-arterial infusion chemotherapy works by puncturing and directly infusing chemotherapy drugs into the arteries to affect the local lesions of the tumor acting as antineoplastons. It is a therapy that not only prevents the first-pass effect in the liver due to systematic chemotherapy and blood distribution affecting the concentration of chemotherapy drugs, but also elevates the local blood concentration of the drugs, extending their time of operation on the tumor, and enhancing the

lethal effect [11, 12]. The present study revealed that the short-term efficacy of intra-arterial infusion chemotherapy was superior to that of systematic (IV) chemotherapy based on the effective rate of 76.47% in the observation group and 48.39% in the control group, which was consistent with the results in the previous literature [13].

CEA and SCCA are highly specific molecular tumor markers used in the clinical diagnosis of many malignant tumors. CEA is a carbohydrate protein existing in the tissues of malignant tumors, such as embryonal tumors, gastroenteric tumors, lung cancer, and urinary system tumors [14, 15]. Muley et al. [16] found that early assisted chemotherapy can significantly reduce the serum CEA level in patients with squamous cell lung carcinoma. Based on this result, they suggested serum CEA as a predictor of the advantages of assisted chemotherapy in the early stages. SCCA is a glycoprotein extensively present in normal tissues at microexpression levels (< 1.5 ng/mL) [17]. Research has shown that [18] SCCA is highly expressed in the tissues and serum of patients with squamous cell carcinoma. The present results indicated that the observation group achieved a more significant reduction in the serum levels of CEA and SCCA than the control group, suggesting that after intra-arterial infusion chemotherapy, patients with advanced cervical cancer experienced more significant reductions in serum levels of CEA and SCCA, as reported previously [19]. The possible reasons include reduced tumor load and reduced serum levels of CEA and SCCA due to chemotherapy. Compared with systematic (IV) chemotherapy, intra-arterial infusion chemotherapy is better in terms of local blood concentration and more prominent in lethal effect, based on which, tumor load is relieved significantly so that the observation group reported more dominant reduction in tumor markers. In addition, the study also showed that the serum levels of CEA and SCCA were reduced in CR and PR patients, while they remained unchanged in NC patients, and increased in PD patients, indicating that serum levels of CEA and SCCA could reflect the tumor load and play a clinical role in judging the effects of chemotherapy.

MVD is a hot topic in tumor development in recent years, which is closely related to the growth and metastasis of malignant tumors,

active growth of vessels, and supply of blood [9]. To develop and progress, malignant tumors require a large amount of blood supply. Studies have revealed that in patients with cervical cancer, MVD and uterine artery hemodynamics are increased to that in healthy populations and patients with benign cervical diseases and are associated with the pathological staging of tumors [20]. VEGF-1, VEGF-C, and VEGF-D are important factors from the VEGF family, of which VEGF-A mainly participates in tumor angiogenesis, and VEGF-C and VEGF-D contribute to lymphangion genesis. These three factors are closely associated with tumor development, progression, and metastasis [21]. Research [16] has shown that in patients with cervical cancer, the serum levels of VEGF-A, VEGF-C, and VEGF-D are significantly higher than those in healthy populations and patients with precancerous lesions of cervical cancer. In the present study, reductions in the uterine artery PI, FI, MVD, and serum VEGF-A, VEGF-C, and VEGF-D were reported and were more significant in the observation group. This clearly indicated that chemotherapy reduced the blood supply to tumors and suppressed angiogenesis. In comparison, the effects of intra-arterial infusion chemotherapy are more obvious, suggesting that uterine artery hemodynamics, MVD, and serum VEGF can be used as important indices of the effects of chemotherapy.

In terms of safety, the incidence of toxic reactions between grades III and IV was slightly lower in the observation group than in the control group ($P > 0.05$). However, in previous studies [20, 22], the toxic reactions due to local intra-arterial infusion chemotherapy were significantly less than those due to systematic (IV) chemotherapy. A possible reason for such a huge difference is the small sample size of the study, which only recorded the incidence of toxic reactions between grades III and IV. The long-term prognosis in the observation group was lower than that in the control group, as indicated by the 1-year and 3-year rates of survival, metastasis, and recurrence, which was consistent with the results of the previous report [23]. This indicated that intra-arterial infusion chemotherapy could improve the prognosis in patients with advanced cervical cancer, reduce metastasis and recurrence, and improve the survival rate.

In summary, in patients with advanced cervical cancer, intra-arterial infusion chemotherapy can improve treatment efficacy as well as the short- and long-term survival, and reduce serum VEGF level, blood flow in tumor, metastasis, and recurrence. Based on its important reference value in the evaluation of chemotherapy effects, the results suggested that serum CEA and SCCA may be potential predicting factors for benefits of chemotherapy.

Disclosure of conflict of interest

None.

Address correspondence to: Lijun Wang and Hai-xiang Yang, Department of Oncology, Baotou Central Hospital, No. 61 Huancheng Road, Donghe District, Baotou 014040, China. Tel: +86-0472-6955464; E-mail: lijunwang102@163.com (LJW); Tel: +86-0472-6955708; E-mail: 1179630395@qq.com (HXY)

References

- [1] Buda A, Lissoni AA, Floriani I, Biagioli E, Gerardi C, Bonazzi C, Chiari S, Locatelli L, Dell'Anna T and Signorelli M. Long-term clinical benefits of neoadjuvant chemotherapy in women with locally advanced cervical cancer. *Int J Gynecol Cancer* 2015; 25: 1468-75.
- [2] Akbaba S, Oelmann-Avendano JT, Bostel T, Rief H, Nicolay NH, Debus J, Lindel K and Foerster R. Percutaneous parametrial dose escalation in women with advanced cervical cancer: feasibility and efficacy in relation to long-term quality of life. *Radiol Oncol* 2018; 52: 320-328.
- [3] Cihoric N, Tsikkinis A, Badra EV, Glatzer M, Novak U, Scherz A, Shelan M, Soldatovic I, Yojena CKK and Aebersold DM. Highly conformal combined radiotherapy with cisplatin and gemcitabine for treatment of loco-regionally advanced cervical cancer-a retrospective study. *Radiol Oncol* 2017; 12: 202.
- [4] Fu ZZ, Li K, Peng Y, Zheng Y, Cao LY, Zhang YJ and Sun YM. Efficacy and toxicity of different concurrent chemoradiotherapy regimens in the treatment of advanced cervical cancer: a network meta-analysis. *Medicine* 2017; 96: e5853.
- [5] Xiao J, Zhou J, Fu M, Liang L, Deng Q, Liu X and Liu F. Efficacy of recombinant human adenovirus-p53 combined with chemotherapy for locally advanced cervical cancer: a clinical trial. *Oncology letters* 2017; 13: 3676-3680.
- [6] Kim JY, Byun SJ, Kim YS and Nam JH. Disease courses in patients with residual tumor following concurrent chemoradiotherapy for locally advanced cervical cancer. *Gynecol Oncol* 2017; 144: 34-39.
- [7] Dahiya N, Bachani D, Acharya AS, Sharma D, Gupta S and Hareesh K. Socio-demographic, reproductive and clinical profile of women diagnosed with advanced cervical cancer in a tertiary care institute of Delhi. *J Obstet Gynaecol India* 2017; 67: 53-60.
- [8] Pomel C, Martinez A, Bourgin C, Beguinot M, Benoit C, Naik R, Dauplat J, Lebouedec G and Ferron G. Survival effect of laparoscopic para-aortic staging in locally advanced cervical cancer: a retrospective cohort analysis. *BJOG* 2017; 124: 1089-1094.
- [9] Koensgen D, Sehoul J, Belau A, Weiss M, Stope MB, Großkopf V, Eichbaum M, Ledwon P, Lichtenegger W and Zygmunt M. Clinical outcome of neoadjuvant radiochemotherapy in locally advanced cervical cancer: results of an open prospective, multicenter phase 2 study of the north-eastern German society of gynecological oncology. *Int J Gynecol Cancer* 2017; 27: 500-506.
- [10] Meng J, Liu S, Zhu L, Zhu L, Wang H, Xie L, Guan Y, He J, Yang X and Zhou Z. Texture Analysis as Imaging Biomarker for recurrence in advanced cervical cancer treated with CCRT. *Sci Rep* 2018; 8: 11399.
- [11] Tewari KS, Sill MW, Penson RT, Huang H, Ramondetta LM, Landrum LM, Oaknin A, Reid TJ, Leitao MM and Michael HE. Bevacizumab for advanced cervical cancer: final overall survival and adverse event analysis of a randomised, controlled, open-label, phase 3 trial (Gynecologic Oncology Group 240). *Lancet* 2017; 390: 1654-1663.
- [12] Pereira E, Cooper HH, Zelaya PG, Creasman W, Price FV, Gupta V and Chuang L. Concurrent chemoradiation versus radiotherapy alone for the treatment of locally advanced cervical cancer in a low-resource setting. *Gynecol Oncol Rep* 2017; 19: 50-52.
- [13] Lucia F, Visvikis D, Desseroit MC, Miranda O, Malhaire JP, Robin P, Pradier O, Hatt M and Schick U. Prediction of outcome using pre-treatment 18 F-FDG PET/CT and MRI radiomics in locally advanced cervical cancer treated with chemoradiotherapy. *Eur J Nucl Med Mol Imaging* 2018; 45: 768-786.
- [14] Benito V, Carballo S, Silva P, Esparza M, Arencibia O, Federico M, Andújar M, Mori M, Medina N and Lubrano A. Should the presence of metastatic para-aortic lymph nodes in locally advanced cervical cancer lead to more aggressive treatment strategies? *J Minim Invasive Gynecol* 2017; 24: 609-616.
- [15] Enwere EK, Kornaga EN, Dean M, Koulis TA, Phan T, Kalantarian M, Köbel M, Ghatage P,

Study of carcinoembryonic antigen and squamous cell carcinoma antigen in cervical cancer

- Magliocco AM and Lees-Miller SP. Expression of PD-L1 and presence of CD8-positive T cells in pre-treatment specimens of locally advanced cervical cancer. *Mod Pathol* 2017; 30: 577.
- [16] Muley T, Rolny V, He Y, Wehnl B, Escherich A, Warth A, Stolp C, Schneider MA, Dienemann H and Meister M. The combination of the blood based tumor biomarkers cytokeratin 19 fragments (CYFRA 21-1) and carcinoembryonic antigen (CEA) as a potential predictor of benefit from adjuvant chemotherapy in early stage squamous cell carcinoma of the lung (SCC). *Lung Cancer* 2018; 120: 46-53.
- [17] Wolf B, Ganzer R, Stolzenburg J-U, Hentschel B, Horn LC and Höckel M. Extended mesometrial resection (EMMR): surgical approach to the treatment of locally advanced cervical cancer based on the theory of ontogenetic cancer fields. *Gynecol Oncol* 2017; 146: 292-298.
- [18] Li P, Zhang R, Nie Z, Long M, Zhang G and Fu Z. Comparison of nedaplatin-and cisplatin-based concurrent chemoradiotherapy in locally advanced cervical cancer patients: a propensity score analysis. *Int J Gynecol Cancer* 2018; 28: 1029-1037.
- [19] Lee J, Lin JB, Chang CL, Sun FJ, Wu MH, Jan YT and Chen YJ. Impact of para-aortic recurrence risk-guided intensity-modulated radiotherapy in locally advanced cervical cancer with positive pelvic lymph nodes. *Gynecol Oncol* 2018; 148: 291-298.
- [20] Wu SG, Zhang WW, Sun JY, Li FY, He ZY and Zhou J. Multimodal treatment including hysterectomy improves survival in patients with locally advanced cervical cancer: a population-based, propensity score-matched analysis. *Int J Surg* 2017; 48: 122-127.
- [21] Jin X, Xu X, Xu H, Lv L and Lu H. The diagnostic value of carcinoembryonic antigen and squamous cell carcinoma antigen in lung adenocarcinoma. *Clin Lab* 2017; 63: 801-808.
- [22] Li J, Wu MF, Lu HW, Zhang BZ, Wang LJ and Lin ZQ. Impact of hyperglycemia on outcomes among patients receiving neoadjuvant chemotherapy for bulky early stage cervical cancer. *PLoS One* 2016; 11: e0166612.
- [23] Choi KH, Lee SW, Yu M, Jeong S, Lee JW and Lee JH. Significance of elevated SCC-Ag level on tumor recurrence and patient survival in patients with squamous-cell carcinoma of uterine cervix following definitive chemoradiotherapy: a multi-institutional analysis. *J Gynecol Oncol* 2018; 30: e1.