

Original Article

The effect of intra-articular injection of antibacterial drugs in the clinical treatment of prosthetic joint infection in patients undergoing artificial hip replacement

Baotie Dong, Hong Li, Wei Gao, Zhendong Zhou

Department I of Orthopedics, The 4th People's Hospital of Shenyang, Shenyang, China

Received November 16, 2020; Accepted December 10, 2020; Epub April 15, 2021; Published April 30, 2021

Abstract: Objective: To study the clinical effect of intra-articular injection of antimicrobials in the treatment of prosthetic joint infection (PJI) in patients undergoing artificial hip replacement surgery and its impact on the quality of life. Methods: A retrospective analysis of the clinical data of 116 patients with PJI after artificial hip replacement in our hospital from June 2016 to June 2017 was performed, and they were randomly divided into a study group and a control group, with 58 in each group. The study group was treated with intra-articular injection of antibacterial drugs, and the control group was injected with sodium hyaluronate. The antibacterial effects of the two groups were compared. Results: The HHS scores of the two groups of patients after treatment increased ($P < 0.001$), and the increase of the study group was more relevant ($P < 0.001$). The IL-17 and IL-6 levels noticeably decreased ($P < 0.001$), and the decrease in the study group was more significant ($P < 0.001$). The total effective rate after 6 weeks of treatment in the study group was evidently higher compared with the control group ($P < 0.05$). The quality of life scores of the two groups of patients after treatment increased ($P < 0.001$), and the the study group was much better ($P < 0.001$). Lower incidence of adverse reactions was identified in the study group ($P < 0.05$). Conclusion: Intra-articular injection of antimicrobials can effectively improve the hip joint function of patients, reduce inflammation, improve the quality of life, and the incidence of adverse reactions is relatively low. It has high clinical application value and is worthy of use and promotion.

Keywords: Antibacterial drugs, artificial hip replacement, prosthetic joint infection, application effect, quality of life

Introduction

Artificial hip replacement is currently the first choice for the treatment of osteoarthritis, aiming to relieve patients' joint pain, correct deformities, restore and improve joint motor function [1, 2]. However, with the promotion and popularization of artificial hip replacement surgery, postoperative infection rates have gradually mounted, and prosthetic joint infection (PJI) is one of the main complications, which seriously affects the patient's postoperative recovery. If not handled properly, it will cause permanent disability. At present, clinical diagnosis is generally performed by collecting postoperative prosthetic tissue or fluid from patients for sample culture, and the diagnosis is confirmed by microbiological results [3, 4]. Bacterial PJI

patients often present with local pain, resting pain, etc., while fungal PJI patients show no typical clinical manifestations plus the disease progress slowly, so it is not easy to diagnose, and ultimately makes the clinical infection more complicated. At present, the second-stage revision of artificial joints is the preferred alternative for the treatment of PJI, that is, to grasp the patient's pathological changes, to insert antibiotic-containing bone cement spacers after removing all prostheses, to use antibiotics for treatment, and to place new prostheses after the infection is eliminated [5, 6]. It can minimize infection, reduce clinical risk, and has high safety. As a kind of high molecular polysaccharide biomaterial, sodium hyaluronate is an important component in joint synovial fluid. It plays a role in lubricating and protecting articu-

lar cartilage, and can improve joint spasms and inhibit cartilage degeneration. However, studies have pointed out that joint pain and swelling may occur after injection in some cases, and even cause shock in severe cases. Thus, the clinical safety needs to be further improved [7, 8]. Antibacterial drugs usually refer to drugs with antibacterial or bactericidal activity, and can effectively inhibit the infection of the tissue around the patient's prosthesis and reduce complications. Based on this, our study was designed to further study the effect of intra-articular injection of antibiotics in artificial hip replacement surgery PJI.

Materials and methods

General information

The clinical data of 116 patients with PJI after artificial hip replacement in our hospital from June 2016 to June 2017 was retrospectively analyzed. The patients were enrolled into a study group and a control group, with 58 cases in each group. In the study group, there were 33 males and 25 females, with an average age of (58.36±4.78) years. Among them, 39 were unilateral onset, 19 were bilateral onset, 26 were traffic accident injuries, 19 were fall injuries, and there were 13 others. In the control group, there were 31 males and 27 females, with an average age of (58.34±4.74) years. Among them, 37 were unilateral, 21 were bilateral, 28 were traffic accident injuries, 20 were fall injuries, and there were 10 others. The clinical data of the two groups were comparable ($P>0.05$).

Inclusion criteria

① Patients undergoing artificial hip replacement surgery; ② Age ≥ 18 years old; ③ The subjects were followed up as planned; ④ This study was approved by the hospital ethics committee, and the patients and their families knew the purpose and procedures of this experimental study, and signed the informed consent form.

Exclusion criteria

① Patients with severe disease of heart, kidney, brain and other organs; ② Patients with cognitive impairment; ③ Patients with metabolic bone disease; ④ Patients with malignant tumors.

Methods

Patients in the control group were treated with intra-articular injection of sodium hyaluronate, and received a puncture at the outer and lower edge of the patella. The patient's joint was bent at 90° and the depression of the lateral knee eye was used as the puncture point. After routine disinfection, the needle was inserted at a 45° angle, and the medicine was slowly injected into the joint cavity, once a week, 25 mg/time, for 8 weeks.

Patients in the study group were treated with intra-articular injection of antibacterial drugs. The vancomycin hydrochloride (SFDA approval number: H20084269; Manufacturer: Zhejiang Hisun Pharmaceutical Co., Ltd.; Specification: 20 mg/bottle) (0.5 g/12 h) was given for 2 weeks through an intravenous drip. At the same time, 15-45 ml fluconazole was injected into the joint cavity of the patient (SFDA approval number: H20000261; Manufacturer: Suicheng Pharmaceutical Co., Ltd.; Specification: 50 mg*3 s) for 2 weeks, and 0.1 g levofloxacin (SFDA approval number: H20000655; Manufacturer: Daiichi Sankyo Pharmaceutical Co., Ltd.; Specification: 0.1 g * 10 s) was orally administered for 8 weeks, 3 times/d. The C-reactive protein (CRP) and erythrocyte sedimentation were analyzed before and after treatment.

Outcome measures

Harris hip score (HHS) [9] was applied to evaluate the motor function of the affected limb before and after treatment. The total score of the scale is 100 points. The higher the score, the better the hip function of the patient.

The fasting venous blood before and after treatment was collected from the two groups of patients, the upper serum was collected after centrifugation, and the levels of IL-17 and IL-6 were determined by enzyme-linked immunosorbent assay (ELISA). The kit was purchased from Shanghai Shuang Ying Biotechnology Co., Ltd.

The operation was performed in accordance with the ELISA kit instructions. (1) Dilute the antigen with the coating diluent to an appropriate concentration, add 100 μ l of antigen to each well, place it at 37°C for 4 h; discard the liquid in the well. (2) Block the enzyme-labeled reaction wells with 5% calf serum and block at

Effect of intra-articular injection of antibacterial drugs

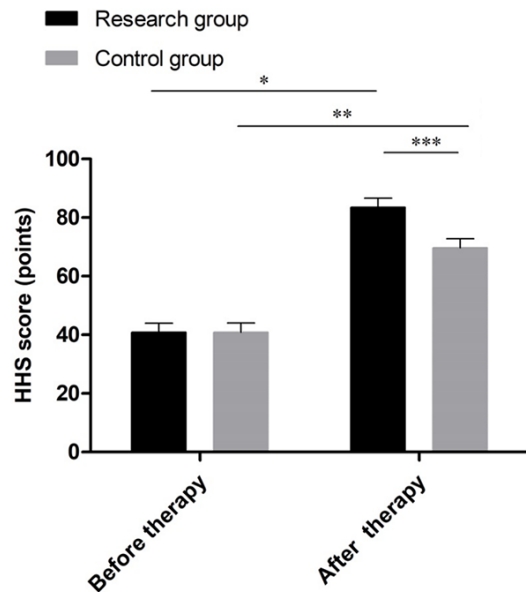


Figure 1. Comparison of HHS scores between the two groups before and after treatment ($\bar{x} \pm sd$). Note: The abscissa represents the data before and after treatment, and the ordinate represents HHS score (points); The HHS scores of the study group before and after treatment were (38.74±4.35) points and (81.27±4.46) points respectively; The HHS scores of the control group before and after treatment were (38.71±4.39) points and (67.52±4.34) points respectively; * indicates that the HHS scores of patients in the study group before and after treatment were significantly different ($t=51.989$, $P=0.000$); ** indicates that the HHS scores of the control group before and after treatment were significantly different ($t=35.543$, $P=0.000$); *** indicates that the HHS scores of the two groups of patients after treatment were significantly different ($t=16.827$, $P=0.000$).

37°C for 40 min. After blocking, wash the wells with cleaning solution 3 times, 3 min each time. (3) Add the sample to be tested, add the diluted sample to the enzyme in the standard reaction wells, 100 μ per well, place at 37°C for 40-60 min, wash the wells with cleaning solution 3 times, 3 min each time. (4) Add enzyme-labeled antibody plus 100 μ l per well, 37°C, for 30-60 min, then wash the wells with cleaning solution 3 times, 3 min each time. Add substrate solution, TMB-Hydrogen Peroxide Urea Solution, 100 μ l per well, place at 37°C in the dark for 3-5 min, add stop buffer to develop color. Stop reaction: add 50 μ l stop buffer to each well to stop the reaction, and measure the results within 20 min.

Clinical control: the clinical symptoms completely disappeared after treatment, the hip joint function recovered, and the imaging

results were normal. Markedly effective: the clinical symptoms basically disappeared, the hip joint activity was not restricted, and the imaging results showed gradual improvement. Effective: clinical symptoms were alleviated, hip joint activity was slightly limited, imaging results improved. Ineffective: clinical symptoms and imaging results showed no significant improvement or even aggravated. Total effective rate = clinical control rate + markedly effective rate + effective rate. The clinical efficacy of the two groups of patients after 6 weeks of treatment was evaluated.

Pain Digital Evaluation Scale [10] was applied to evaluate the physical pain. The full score of the scale is 10 points. The higher the score, the stronger the patient's physical pain. The Quality of Life Score Scale for Hip Replacement Patients was used to evaluate the quality of life. The total score of the scale is 60 points, with a score of 51-60 as excellent; 41-50 as good, 31-40 as general, 21-30 as poor, and less than 20 as extremely poor.

The adverse reactions of the two groups of patients after treatment were compared.

Statistical methods

The experimental data were statistically analyzed and processed by SPSS 20.0 software. Counting data were expressed as [n (%)] and compared by chi-squared test, and measurement data were represented by ($\bar{x} \pm sd$) and run by t test. $P < 0.05$ means that there was a statistically significant difference.

Results

Comparison of general data

In the study group, there were 33 males and 25 females, with an average age of (58.36±4.78) years. In the control group, there were 31 males and 27 females, with an average age of (58.34±4.74) years.

Comparison of HHS scores

Before treatment, the difference in HHS scores between the two groups of patients was not statistically significant; after treatment, HHS of the study group of patients was higher than that of the control group ($t=16.827$, $P=0.000$); and the HHS of the two groups after treatment was higher than that before treat-

Effect of intra-articular injection of antibacterial drugs

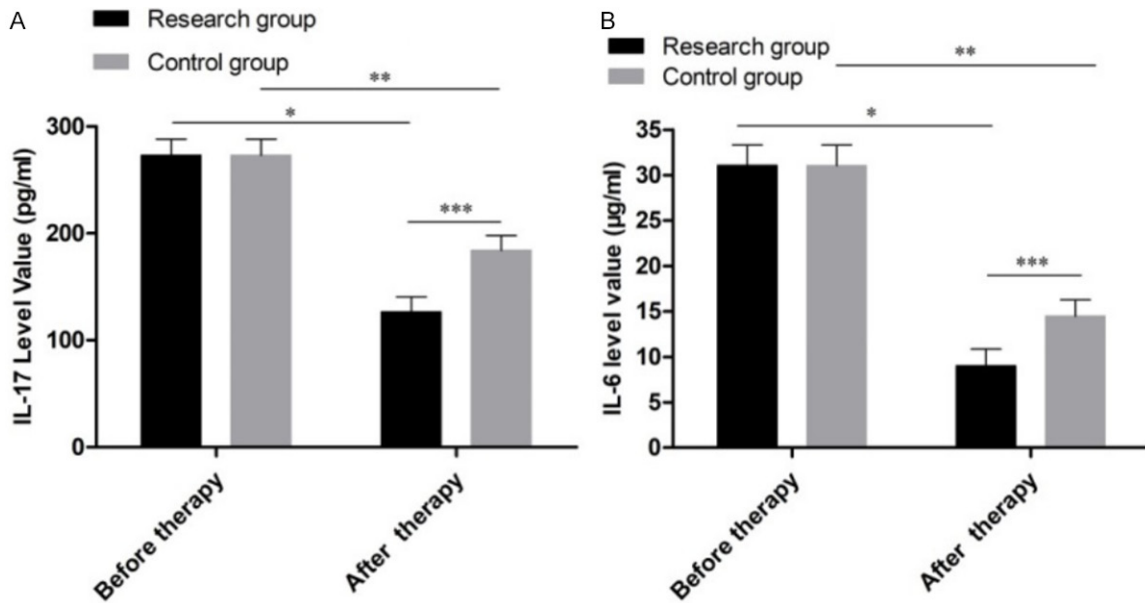


Figure 2. Comparison of IL-17 and IL-6 levels before and after treatment between the two groups ($x \pm sd$). Note: (A) The abscissa indicates the data before and after treatment, and the ordinate indicates the level of IL-17 (pg/ml); The IL-17 levels of patients in the study group before and after treatment were (262.41±21.35) pg/ml and (116.68±19.74) pg/ml, respectively; The IL-17 levels of patients in the control group before and after treatment were (262.38±21.38) pg/ml and (174.55±19.32) pg/ml respectively; * indicating that the IL-17 levels of patients in the study group were significantly different before and after treatment ($t=38.169$, $P=0.000$); ** indicates that there was a significant difference in the IL-17 levels of the control group before and after treatment ($t=23.212$, $P=0.000$); *** indicates that there was a significant difference in IL-17 levels after treatment between the two groups ($t=15.956$, $P=0.000$). (B) The abscissa indicates the data before and after treatment, and the ordinate indicates the level of IL-6 ($\mu\text{g/ml}$); The IL-6 levels of patients in the study group before and after treatment were (29.47±3.19) $\mu\text{g/ml}$ and (7.74±2.58) $\mu\text{g/ml}$ respectively; The IL-6 levels of patients in the control group before and after treatment were (29.44±3.21) $\mu\text{g/ml}$ and (13.22±2.54) $\mu\text{g/ml}$ respectively; * indicating that the IL-6 levels of patients in the study group were significantly different before and after treatment ($t=40.337$, $P=0.000$); ** indicates that there was a significant difference in the IL-6 levels of the control group before and after treatment ($t=30.178$, $P=0.000$); *** indicates that there was a significant difference in the IL-6 levels of the two groups of patients after treatment ($t=11.527$, $P=0.000$).

ment ($t=51.989$, 35.543 , $P=0.000$), as shown in **Figure 1**.

Comparison of IL-17 levels and IL-6 levels

Before treatment, there was no significant difference in IL-17 levels and IL-6 levels between the two groups of patients; after treatment, the IL-17 levels and IL-6 levels of the study group patients were lower than those of control group patients ($t=15.956$, 11.527 , $P=0.000$); and the IL-17 levels and IL-6 levels of the two groups after treatment were lower than those before treatment ($t=38.169$, 23.212 , 40.337 , 30.178 , $P=0.000$), see **Figure 2A**, **2B**.

Comparison of clinical effects after 6 weeks of treatment

After 6 weeks of treatment, the total effective rate of patients in the study group was dramati-

cally higher than that in the control group ($P < 0.05$), as shown in **Table 1**.

Comparison of the quality of life scores

Before treatment, the difference of the quality of life scores between the two groups of patients was not statistically significant. After treatment, the VAS score of the study group patients was lower than the control group ($P < 0.05$), and the score of quality of life was higher than the control group ($P < 0.05$), as shown in **Table 2**.

Comparison of clinical adverse reactions

In the study group, there was 1 case of hematoma, 1 case of neurovascular injury, no dislocation or bone fracture. In the control group, there were 3 cases of hematoma, 2 cases of dislocation, 1 case of bone fracture, and 3

Effect of intra-articular injection of antibacterial drugs

Table 1. Comparison of clinical efficacy between the two groups of patients after 6 weeks of treatment [n (%)]

| Groups | n | Clinical control | Markedly effective | Effective | Ineffective | Total effective rate |
|---------------|----|------------------|--------------------|-------------|-------------|----------------------|
| Study group | 58 | 14 (24.14%) | 22 (37.93%) | 18 (31.03%) | 4 (6.90%) | 93.10% (54/58) |
| Control group | 58 | 9 (15.52%) | 17 (29.31%) | 17 (29.31%) | 15 (25.86%) | 74.14% (43/58) |
| χ^2 | | | | | | 7.616 |
| p | | | | | | 0.006 |

Table 2. Comparison of the quality of life scores of the two groups of patients before and after treatment ($\bar{x}\pm s$, points)

| Groups | n | VAS score | | t | P | Score of quality of life | | t | P |
|---------------|----|------------------|------------------|--------|---------|--------------------------|-------------------|--------|---------|
| | | Before treatment | After treatment | | | Before treatment | After treatment | | |
| Study group | 58 | 7.46 \pm 1.48 | 3.17 \pm 1.06 | 11.442 | < 0.001 | 25.31 \pm 5.38 | 49.57 \pm 5.78 | 15.877 | < 0.001 |
| Control group | 58 | 7.44 \pm 1.51 | 5.74 \pm 1.18* | 10.235 | < 0.001 | 25.34 \pm 5.36 | 32.79 \pm 5.69* | 20.412 | < 0.001 |
| t | | 0.072 | 12.339 | | | 0.03 | 15.756 | | |
| P | | 0.943 | < 0.001 | | | 0.976 | < 0.001 | | |

Note: The VAS scores and quality of life scores of the two groups of patients after treatment were significantly better than those before intervention; *indicates that the study group and the control group after treatment are compared, $P < 0.05$.

Table 3. Comparison of adverse reactions between the two groups of patients [n (%)]

| Groups | n | hematoma | dislocation | Bone fracture | neurovascular injury | Total incidence rate |
|---------------|----|-----------|-------------|---------------|----------------------|----------------------|
| Study group | 58 | 1 (1.72%) | 0 (0.00%) | 0 (0.00%) | 1 (1.72%) | 3.45% (2/58) |
| Control group | 58 | 3 (5.17%) | 2 (3.45%) | 1 (1.72%) | 3 (5.17%) | 15.52% (9/58) |
| χ^2 | | | | | | 4.921 |
| p | | | | | | 0.027 |

cases of neurovascular injury. Lower total incidence of adverse reactions was identified in the study group ($P < 0.05$), see **Table 3**.

Comparison of CRP and ESR

Before treatment, there was no significant difference in CRP and ESR between the two groups of patients; after treatment, the CRP and ESR of the two groups were lower than before treatment, and the CRP and ESR of the study group were lower than those of the control group ($P < 0.05$). See **Table 4**.

Discussion

Along with the aging advancement in China, the number of patients with bone injuries has raised every year, leading to an increase in artificial hip replacement. Hip replacement is currently a mature method of clinical treatment of hip diseases, which can correct deformed joints, promote the restoration of the original function of the hip joint, fundamentally reduce

the patient's physical discomfort and pain, and improve the quality of life. However, complications will occur after surgery, which will not only compromise the treatment effect, but also risk the patient's life in severe cases. Therefore, the complications after artificial hip replacement have gradually attracted the attention of society and medical staff [11-13]. So far, no uniform standard for the dosage and time of antibiotics use has been developed in clinical practice. After antibiotics enter the human body, they will interfere with the development of other cells and have inhibitory and killing effects on all living substances in the body. For this reason, the use of antibiotics should be based on the patient's condition and physical signs. Close attention should be paid to the patient's various physiological indicators when using antibiotics to reduce the damage to liver and kidney function [14, 15].

HHS score is essential to comprehensively evaluate the motor function of the hip joint [16]. This study showed that the HHS scores of the

Effect of intra-articular injection of antibacterial drugs

Table 4. Comparison of CRP and ESR between two groups of patients before and after treatment

| Groups | n | CRP (mg/L) | | t | P | ESR (mm/h) | | t | P |
|---------------|----|------------------|---------------------------|--------|---------|------------------|---------------------------|--------|---------|
| | | Before treatment | After treatment | | | Before treatment | After treatment | | |
| Study group | 58 | 31.2±8.41 | 13.47±3.05 ^{*,*} | 17.869 | < 0.001 | 31.21±8.4 | 10.57±2.77 ^{*,*} | 20.152 | < 0.001 |
| Control group | 58 | 30.9±8.52 | 18.72±4.38 [#] | 16.541 | < 0.001 | 31.34±8.39 | 13.89±3.69 [#] | 21.478 | < 0.001 |
| t | | 0.191 | 7.491 | | | 0.072 | 5.48 | | |
| P | | 0.949 | 0.001 | | | 0.899 | < 0.001 | | |

Note: ^{*}indicates that CRP and ESR of the two groups of patients after treatment were significantly lower than those before treatment, $P < 0.05$; [#]indicates that CRP and ESR of study group were lower than those of the control group, $P < 0.05$.

two groups after treatment significantly increased, with the study group more significant, suggesting that both treatment methods can improve the patient's hip joint function and intracavity injection of antibacterial drugs is more effective. Studies pointed out [17] that the internal structure of fungal biofilms is more complex than other pathogens, and high concentrations of antifungal drugs are needed to inhibit its growth. In our study, patients were injected with vancomycin and fluconazole and other antifungal drugs. The levels of IL-17 and IL-6 in the study group were much lower, suggesting that this treatment method can effectively reduce the body's inflammatory response and speed up limb recovery. Lingyun Zhou et al. [18] believed that by directly injecting antibiotics into the joint cavity, higher drug concentration can be obtained, and systemic toxicity can be avoided at the same time, which is safer. Ashraf S. Hassan et al. [19] confirmed the clinical efficacy of fluconazole and amphotericin B in the study, and pointed out that fluconazole is more effective than amphotericin B in the treatment of histoplasmosis. Amphotericin B has a strong toxicity and a high incidence of adverse reactions, so this experiment only used fluconazole for treatment.

Lanas et al. [20] found that when PJI patients were given intraarticular injection of antibiotics, their quality of life score after treatment was (48.73±4.38) points, dramatically higher than the control group (33.82±4.25) points. It is suggested that this treatment method can improve the quality of life of patients with PJI and is beneficial to the recovery of hip joint function. There are also some limitations about this study: it is a retrospective study with a small size of sample; there may be selection and recall biases; some differences exist in treatment techniques and medical equipment. Therefore, large-scale

studies are still needed to further refine the results.

To conclude, the use of intra-articular injection of antibacterial drugs in the treatment of PJI patients undergoing artificial hip replacement can significantly improve the hip joint function, reduce inflammation, and improve the quality of life. It has high clinical application value and is worthy of further promotion.

Disclosure of conflict of interest

None.

Address correspondence to: Baotie Dong, Department I of Orthopedics, The 4th People's Hospital of Shenyang, No. 20, South Huanghe St, Shenyang City, China. Tel: +86-13998804507; E-mail: Baotie_Dong@126.com

References

- [1] Ramdhani S, Saputra E and Jamari J. Numerical simulation of artificial hip joint motion based on human age factor. *J Phys Conf Ser* 2018; 1025: 012093.
- [2] Zhang D, Liu H, Wang J, Sheng C and Li Z. Wear mechanism of artificial joint failure using wear debris analysis. *J Nanosci Nanotechnol* 2018; 18: 6805-6814.
- [3] Błażkiewicz M and Wit A. Artificial neural network simulation of lower limb joint angles in normal and impaired human gait. *Acta Bioeng Biomech* 2018; 20: 43-49.
- [4] Zhang H, Cheng G, Shan X and Li Y. Singularity-free path optimization of the parallel test mechanism for artificial hip joints. *J Mech Sci Tech* 2018; 32: 1775-1786.
- [5] Pezzotti G, Zhu W, Sugano N, Marin E, Yamamoto K, Nishiike N, Hori T, Rondinella A, McEntire BJ, Bock R and Sonny Bal B. Oxide ceramic femoral heads contribute to the oxidation of polyethylene liners in artificial hip joints.

Effect of intra-articular injection of antibacterial drugs

- J Mech Behav Biomed Mater 2018; 82: 168-182.
- [6] Basri H, Syahrom A, Prakoso A, Wicaksono D, Ammarullah MI, Ramadhoni T and Nugraha R. The analysis of dimple geometry on artificial hip joint to the performance of lubrication. J Phys Conf Ser 2019; 1198: 042012.
- [7] Xu H, Zhang D, Chen K and Zhang T. Taper fretting behavior of PEEK artificial hip joint. Tribol Int 2019; 137.
- [8] Braun S, Sonntag R, Schroeder S, Mueller U, Jaeger S, Gotterbarm T and Kretzer JP. Backside wear in acetabular hip joint replacement. Acta Biomater 2019; 83: 467-476.
- [9] Kalhapure RS, Bolla P, Dominguez DC, Dahal A, Boddu SHS and Renukuntla J. FSE-Ag complex NS: preparation and evaluation of antibacterial activity. IET Nanobiotechnol 2018; 12: 836-840.
- [10] Mantero M, Rogliani P, Cazzola M, Blasi F and Di Pasquale M. Emerging antibacterial and antiviral drugs for treating respiratory tract infections. Exp Opin Emerg Drugs 2018; 23: 185-199.
- [11] Shulenina O, Yarovoy B, Kirillov S, Paleskava A and Konevega A. Potential antibacterial drugs from unique collection of yeast-like fungi. J Bioener Biomembranes 2018; 233.
- [12] Li S, Dong S, Xu W, Tu S, Yan L, Zhao C, Ding J and Chen X. Antibacterial hydrogels. Adv Sci (Weinh) 2018; 5: 1700527.
- [13] Eldesouky HE, Mayhoub A, Hazbun TR and Seleem MN. Reversal of azole resistance in candida albicans by sulfa antibacterial drugs. Antimicrob Agents Chemother 2018; 62: e00701-17.
- [14] Feier A, Radu-Cristian I, Ioanovici A, Tamas T and Russu O. Biofilm inhibition: compounds with antibacterial effects. J Interd Med 2018; 3.
- [15] Xu W, Dong S, Han Y, Li S and Liu Y. Hydrogels as antibacterial biomaterials. Curr Pharmacol Design 2018; 24: 843-854.
- [16] Ozdemir Z, Tras B and Uney K. Distribution of hydrophilic and lipophilic antibacterial drugs in skim milk, cream, and casein. J Dairy Sci 2018; 101: 10694-10702.
- [17] Brochado AR, Telzerow A, Bobonis J, Banzhaf M, Mateus A, Selkrig J, Huth E, Bassler S, Zamarréño Beas J, Zietek M, Ng N, Foerster S, Ezraty B, Py B, Barras F, Savitski MM, Bork P, Göttig S and Typas A. Species-specific activity of antibacterial drug combinations. Nature 2018; 559: 259-263.
- [18] Zhou L, Qiu T, Lv F, Liu L, Ying J and Wang S. Self-assembled nanomedicines for anticancer and antibacterial applications. Adv Healthcare Mater 2018; 7: e1800670.
- [19] Hassan A, Moustafa G, Askar A, Naglah A and Al-Omar M. Synthesis and antibacterial evaluation of fused pyrazoles and Schiff bases. Synthetic Commun 2018: 1-12.
- [20] González A, Fillat MF and Lanás Á. Transcriptional regulators: valuable targets for novel antibacterial strategies. Future Med Chem 2018; 10: 541-560.