

Erratum

Exosomes released by human umbilical cord mesenchymal stem cells protect against renal interstitial fibrosis through ROS-mediated P38MAPK/ERK signaling pathway: Am J Transl Res. 2020; 12(9): 4998-5014

Bo Liu^{1,2}, Dong Hu², Yu Zhou², Yihang Yu², Lianju Shen², Chunlan Long², Denis Butnaru³, Peter Timashev³, Dawei He¹, Tao Lin¹, Tao Xu⁴, Deying Zhang^{1,2}, Guanghui Wei^{1,2}

¹Department of Urology, Children's Hospital of Chongqing Medical University, Chongqing 400014, China; ²Ministry of Education Key Laboratory of Child Development and Disorders, Chongqing Key Laboratory of Pediatrics, Chongqing International Science and Technology Cooperation Center for Child Development and Disorders, Chongqing 400014, China; ³Institute for Regenerative Medicine, Sechenov University, 8-2 Trubetskaya St., Moscow 119991, Russia; ⁴Department of Mechanical Engineering, Biomanufacturing Center, Tsinghua University, Beijing 100084, China

Received January 23, 2021; Accepted February 4, 2021; Epub April 15, 2021; Published April 30, 2021

During the final submission of high-resolution figures for this manuscript's publication, the images in **Figure 6Aj** were inadvertently replaced with images from published **Figure 6Aj**. The published version of **Figure 6Aj** is therefore incorrect. The corrected version of the figure, as originally submitted and reviewed in all versions before the last, is shown below. The only change is in the panels of **Figure 6Aj**; the rest of the figure is identical to the published version. All of the published results and conclusions of the paper remain unchanged. We apologize for

this oversight and for any confusion that it has caused.

Address correspondence to: Drs. Deying Zhang and Guanghui Wei, Department of Urology, Children's Hospital of Chongqing Medical University, No. 136, Zhongshan 2 RD, Yuzhong District, Chongqing 400014, China. Tel: +86-13594136249; E-mail: zdy@hospital.cqmu.edu.cn (DYZ); Tel: +86-1388-3517399; E-mail: u806806@cqmu.edu.cn (GHW)

hucMSC-Ex protect against renal fibrosis

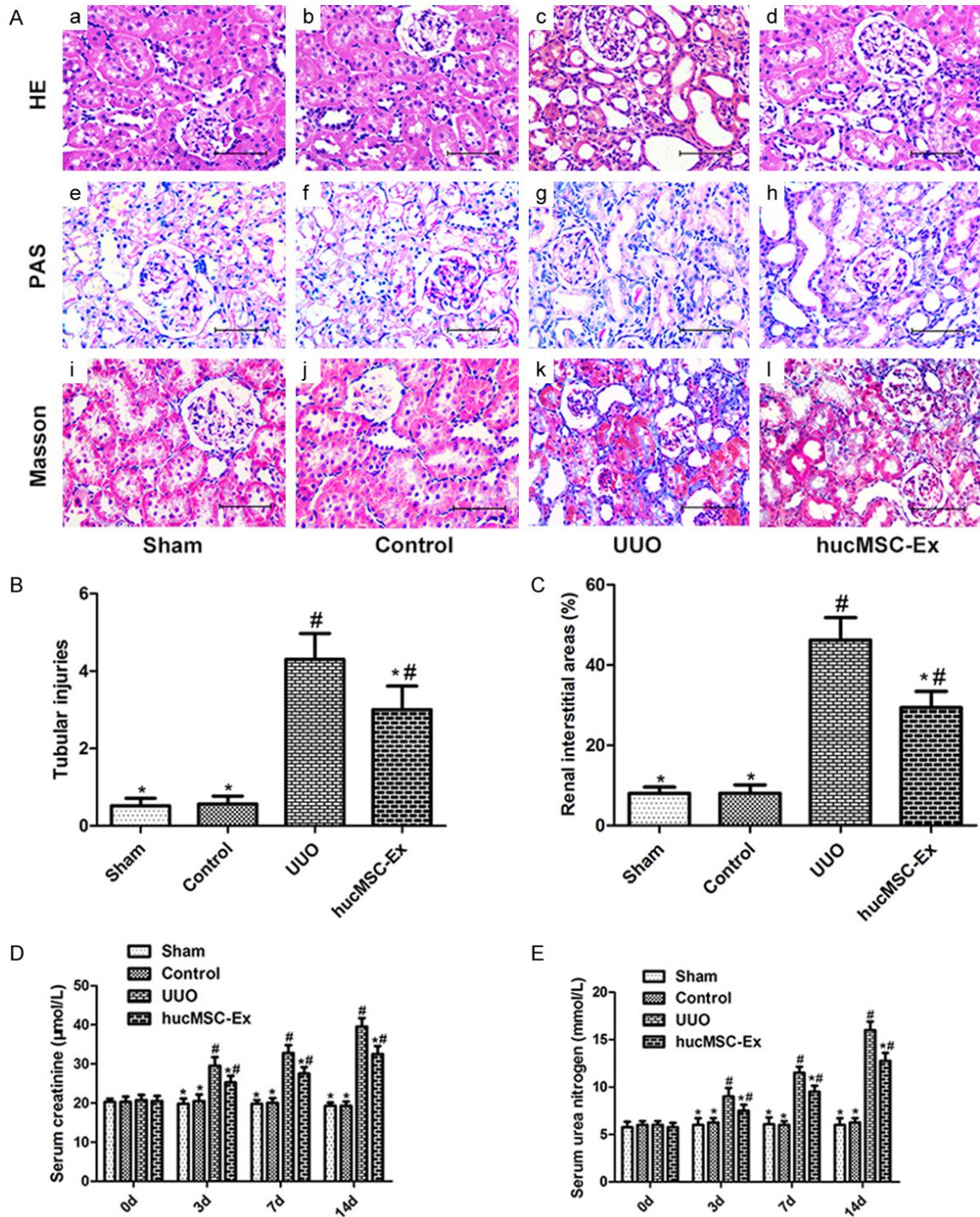


Figure 6. The effect of hucMSC-Ex on the histopathology and function of UUO-induced kidneys. (A) Histopathology analysis of the kidney in each group. (a-d) H&E staining, (e-h) PAS staining, (i-l) Masson's trichrome staining. (B) Tubular damage was scored by calculation of the percentage of tubules that displayed cell necrosis, loss of the brush border, cast formation, and tubular dilatation. (C) Area of renal interstitial fibrosis in each group. (D, E) BUN and Scr values in each group at 0, 3, 7, 14 days. Values presented as mean ± SD. *P<0.05 versus UUO group; #P<0.05 versus sham and control group. BUN blood urea nitrogen, Ex exosome, HE hematoxylin-eosin, hucMSC human umbilical cord-derived mesenchymal stem cell, PAS periodic acid schiff, Scr serum creatinine, UUO unilateral ureteral obstruction.